

See discussions, stats, and author profiles for this publication at: <https://www.researchgate.net/publication/361974988>

# Case Report: Incidental finding of didelphys uterus in a multigravida woman at Caesarean delivery

Article in *F1000Research* · July 2022

DOI: 10.12688/f1000research.123141.1

CITATIONS

2

READS

160

3 authors, including:



**Olutosin Alaba Awolude**

University of Ibadan/University College Hospital Ibadan, Nigeria

104 PUBLICATIONS 1,371 CITATIONS

SEE PROFILE

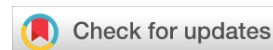

**Gbolahan Oladele Obajimi**

69 PUBLICATIONS 195 CITATIONS

SEE PROFILE

UNIVERSITY OF IBADAN LIBRARY



## CASE REPORT

# Case Report: Incidental finding of didelphys uterus in a multigravida woman at Caesarean delivery [version 1; peer review: 1 approved]

Olutosin Awolude <sup>1,2</sup>, Ademola Olutoye <sup>2</sup>, Gbolahan Obajimi<sup>1,2</sup>

<sup>1</sup>Obstetrics and Gynaecology Department, College of Medicine, University of Ibadan, Ibadan, Oyo, 241000, Nigeria

<sup>2</sup>Obstetrics and Gynaecology Department, University College Hospital, Ibadan, Ibadan, Oyo, 241000, Nigeria

**V1** First published: 13 Jul 2022, 11:789  
<https://doi.org/10.12688/f1000research.123141.1>

Latest published: 13 Jul 2022, 11:789  
<https://doi.org/10.12688/f1000research.123141.1>

## Abstract

Didelphys uterus is one of the rarest Müllerian duct anomalies (MDA) of the female genital tract. Many remain undiagnosed due to possibilities of successful pregnancies and vaginal deliveries in those without or with mild forms of associated cervical and/or vaginal anomalies. Due to this, data on didelphys uterus in pregnancy are rare, with most cases seen during routine ultrasound in pregnancies' Caesarean section for other obstetric indications. This case was a 36-year-old G4P1<sup>+</sup>2 female who had successful vaginal delivery in her preceding pregnancy; in index pregnancy, she presented with fetal footling breech in labour and had an emergency caesarean section during which uterine didelphys was diagnosed. Many pregnant women with didelphys uterus will deliver vaginally and, as such, remain undiagnosed. Its presence is one of the possible reasons for persistent abnormal presentations like fetal breech presentation, especially in women with prior successful vaginal deliveries. Early recognition and availability of facilities for management of such incidentally found cases of uterine didelphys will prevent many of the complications associated with pregnancy with them.

## Keywords

uterine didelphys, pregnancy, caesarean section, breech presentation

## Open Peer Review

Approval Status

1

### version 1

13 Jul 2022



[view](#)

1. **Adepiti Clement Akinfolarin**, The Obafemi Awolowo University, Ile-Ife, Nigeria

Any reports and responses or comments on the article can be found at the end of the article.

**Corresponding author:** Olutosin Awolude ([tosinawolude@yahoo.com](mailto:tosinawolude@yahoo.com))

**Author roles:** **Awolude O:** Conceptualization, Data Curation, Methodology, Project Administration, Resources, Supervision, Validation, Visualization, Writing – Original Draft Preparation, Writing – Review & Editing; **Olutoye A:** Data Curation, Investigation, Methodology, Project Administration, Validation, Visualization, Writing – Original Draft Preparation, Writing – Review & Editing; **Obajimi G:** Data Curation, Investigation, Methodology, Project Administration, Supervision, Validation, Visualization, Writing – Review & Editing

**Competing interests:** No competing interests were disclosed.

**Grant information:** The author(s) declared that no grants were involved in supporting this work.

**Copyright:** © 2022 Awolude O *et al.* This is an open access article distributed under the terms of the [Creative Commons Attribution License](#), which permits unrestricted use, distribution, and reproduction in any medium, provided the original work is properly cited.

**How to cite this article:** Awolude O, Olutoye A and Obajimi G. **Case Report: Incidental finding of didelphys uterus in a multigravida woman at Caesarean delivery [version 1; peer review: 1 approved]** F1000Research 2022, 11:789

<https://doi.org/10.12688/f1000research.123141.1>

**First published:** 13 Jul 2022, 11:789 <https://doi.org/10.12688/f1000research.123141.1>

UNIVERSITY OF IBADAN LIBRARY

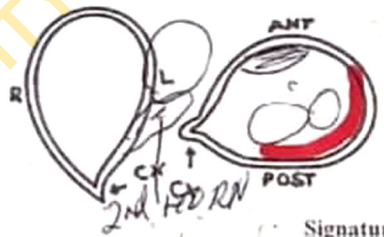## Introduction

Müllerian duct abnormalities (MDA) are a spectrum of genital abnormalities arising from failure of fusion of the Müllerian ducts during the embryological stage of development.<sup>1</sup> The prevalence of congenital uterine anomalies varies and can range between 5.5% in the general population and 24.5% in patients treated for miscarriages and infertility.<sup>2</sup> The most common forms of uterine anomalies include unicornuate uterus, bicornuate uterus, arcuate uterus, septate uterus and didelphys uterus. Uterine didelphys belongs to MDA class III as defined by American Society of Reproductive Medicine (ASRM). This classification includes adnexal adhesions, distal tubal occlusion, tubal occlusion secondary to tubal ligation, tubal pregnancies, Müllerian anomalies and intrauterine adhesions that result from failure of Müllerian duct fusion at week eight of gestation.<sup>3,4</sup> Though uterine didelphys rarely affects fertility, it is commonly associated with adverse pregnancy outcomes such as recurrent miscarriages, preterm deliveries, intrauterine growth-restricted fetuses, low-birth-weight fetuses, and fetal malpresentations. While many cases will remain undiagnosed until evaluations for other gynaecological conditions,<sup>5,6</sup> fetal malpresentation diagnosed during pregnancy or at delivery is one of the commonest indications for Caesarean delivery.<sup>7</sup> We present a case of Caesarean section in a multiparous woman with uterine didelphys with breech presentation at term in our obstetric service.

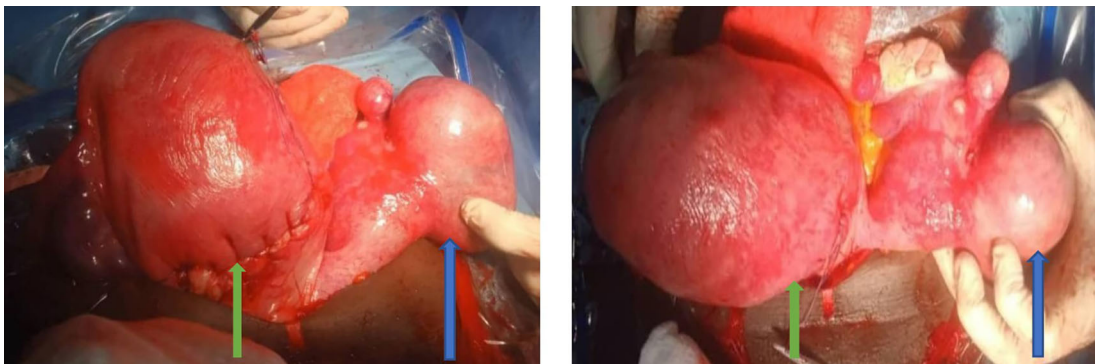
## Case

A 36-year-old G4P1<sup>+2</sup> 1 alive Nigerian of Yoruba ethnicity, presented for antenatal service following spontaneous conception of singleton gestation at gestational age of 17 weeks. She was the third of her parents' four children, including three females and one male. The older two sister were multiparous with no significant obstetric complaints. Obstetrics scan done at 23 weeks revealed live singleton fetus in breech presentation within the right horn and empty left horn of the uterus (Figure 1). She was regular at clinic visits and her pregnancy period remained uneventful. Four years earlier, she had a vaginal delivery, at term, of a live neonate with a birth weight of 2.95 kg following spontaneous conception after two prior spontaneous pregnancies loss at about six weeks gestation each.

Review at the antenatal clinic at 37 weeks revealed fetal cephalic presentation at clinical examination. However, at 38 weeks and four days of gestation she presented in labour and obstetrics examination revealed a singleton fetus in longitudinal lie with footling breech presentation. She subsequently had emergency lower segment Caesarean section and was delivered of a live neonate with a birth weight of 3.75 kg via breech extraction from the right horn, the left horn was bulky and equivalent to about 14 weeks size gestation (Figure 2). Each horn had its adjoining normal looking fallopian tube and ovary. The urinary bladder was grossly normal. Her postoperative period was satisfactory and she was discharged on fourth day after surgery.



**Figure 1.** Sonologist impression of the uterine didelphys with pregnancy in the right horn.



**Figure 2.** Double uteri at caesarean section with suture right horn that contained the fetus (green arrow) and the empty left horn (blue arrow).

## Discussion

Congenital malformations of the female genital tract are embryological maldevelopments of the Müllerian or paramesonephric ducts.<sup>8,9</sup> The prevalence of genital tract malformations has been reported to vary between 6.0-38%.<sup>9,10</sup> In the general population it was reported to range between 5-7%, 7-8% in the infertile population and 16-25% in the recurrent miscarriage and infertile population.<sup>1,8,11</sup> Malformations involving the uterus have been reported as the most common MDA with septate uterus being the commonest, and didelphys uterus the rarest.<sup>12</sup> In a 15-year retrospective analysis, septate uterus were found in 55.6% of cases of female genital tract anomaly, while uterine didelphys accounted for 22.7% of cases.<sup>13</sup> Presentations of genital tract anomalies also vary. In paediatric patients, presentation to emergency services with symptoms of severe abdominal pain, likely associated dysmenorrhea if menarche has been reached, obstructed hemivaginal septa, and abdominal swelling from haematometra with or without haematocolpos, are common.<sup>1,14</sup>

Congenital malformation of the female genital tract is of special interest in the practice of obstetrics as the obstetric performance is determined by the type of MDA. Some authors have reported increased risk of first- and second-trimester miscarriages, preterm birth, low birth weight, fetal mal-presentation, and ultimately abdominal delivery with uterine didelphys.<sup>15,16</sup> However, there have been many reported cases of successful pregnancies and deliveries in patients with uterine didelphys following appropriate pre-pregnancy surgical correction and appropriate obstetrics interventions like cervical cerclage.<sup>1,17</sup> In a prospective multicenter study of 286 pregnant women with uterine didelphys conducted in Saudi Arabia, 5.2% of the women had first trimester abortion, 27.5% had preterm labour which were managed conservatively with all delivering at term and of all delivering at term, 5.9% had spontaneous vaginal delivery, 13.3% had operative vaginal delivery and 80.8% of the women delivered by Caesarean section.<sup>18</sup> Our patient had two previous miscarriages prior to her first delivery.

Delivery by Caesarean section is, generally, not primarily indicated in cases of uterine didelphys except for additional obstetric indication.<sup>19</sup> In our patient, she had successful vaginal delivery in her previous pregnancy and had Caesarean delivery in index case because of the fetal footling breech presentation at term.

## Conclusions

Didelphys uterus is among the rarest of Müllerian duct anomalies and is commonly associated with successful pregnancies outcomes. Many will deliver vaginally and remain undiagnosed, as was the case for the first term pregnancy of the case we presented. However, its presence can be suspected in pregnant women with prior vaginal deliveries now presenting with malpresentations, like persistent fetal breech presentation as seen in this patient. Good antenatal care and management in a facility with adequate obstetric facilities for surgical intervention can prevent complications that can result from undiagnosed cases. This is especially important for cases showing malpresentations as seen in this case of fetal footling breech presentation.

## Data availability

All data underlying the results are available as part of the article and no additional source data are required.

## Patient consent

Consent was obtained from the patient for publication of this case.

## References

- Jorgensen C, Lusiak M: **Didelphys Uterus in Pregnancy, an Uncommon Mullerian Duct Anomaly: A Case Report.** *Clin. Pract. Cases Emerg. Med.* 2021; **5**(4): 447–449. [PubMed Abstract](#) | [Publisher Full Text](#)
- Chan Y, Jayaprakasan K, Zamora J, et al.: **The prevalence of congenital uterine anomalies in unselected and high-risk populations: A systematic review.** *Hum. Reprod. Update.* 2011; **17**: 761–771. [PubMed Abstract](#) | [Publisher Full Text](#)
- The American Fertility Society **The American Fertility Society classifications of adnexal adhesions, distal tubal occlusion, tubal occlusion secondary to tubal ligation, tubal pregnancies, Mullerian anomalies and intrauterine adhesions.** *Fertil. Steril.* 1988; **49**: 944–955. [PubMed Abstract](#) | [Publisher Full Text](#)
- Grimbizis GF, Gordts S, Sardo ADS, et al.: **The ESHRE/ESGE consensus on the classification of female genital tract congenital anomalies.** *Hum. Reprod.* 2013; **28**: 2032–2044. [PubMed Abstract](#) | [Publisher Full Text](#)
- Martínez-Beltrán M, Giménez JP: **Uterus didelphys with septate cervix and unilateral endometrial carcinoma: A case report.** *J. Genit. Syst. Disord.* 2012; **1**(1). [Publisher Full Text](#)
- Rezai S, Bisram P, Alcantara I, et al.: **Didelphys uterus: A case report and review of the literature.** *Case Report. Obstet. Gynecol.* 2015; **2015**: 865821. [PubMed Abstract](#) | [Publisher Full Text](#)

7. Maiti GD, Tugnait P, Anand AK, *et al.*: **Uterine Didelphys with Pregnancy and Cervical Incompetence.** *Med. J. Armed Forces India.* 2006; **62**(2): 200–201.  
[PubMed Abstract](#) | [Publisher Full Text](#)
8. Gao J, Zhang J, Tian W, *et al.*: **Endometrial cancer with congenital uterine anomalies: 3 case reports and a literature review.** *Cancer Biol. Ther.* 2017; **18**(3): 123–131.  
[Publisher Full Text](#)
9. Laufer MR, De Cherney AH: *Clinical Manifestations and Diagnosis of Congenital Anomalies of the Uterus.* UpToDate. Waltham, MA, USA: Wolters Kluwer; 2019. South Holland, The Netherlands.
10. Kim MA, Kim HS, Kim YH: **Reproductive, Obstetric and Neonatal Outcomes in Women with Congenital Uterine Anomalies: A Systematic Review and Meta-Analysis.** *J. Clin. Med.* 2021; **10**(21): 4797.  
[PubMed Abstract](#) | [Publisher Full Text](#)
11. Saravelos SH, Cocksedge KA, Li TC: **Prevalence and diagnosis of congenital uterine anomalies in women with reproductive failure: a critical appraisal.** *Hum. Reprod. Update.* 2008; **14**(5): 415–429.  
[PubMed Abstract](#) | [Publisher Full Text](#)
12. Simón C, Martínez L, Pardo F, *et al.*: **Müllerian defects in women with normal reproductive outcome.** *Fertil. Steril.* 1991; **56**(6): 1192–1193.  
[Publisher Full Text](#)
13. Wang SJ, Oli M, Jinag L, *et al.*: **Clinical analysis of 225 women with congenital uterine malformation.** *Zhonghua Fu Chan Ke Za Zhi.* 2008; **43**(7): 493–496.  
[PubMed Abstract](#)
14. Karaca L, Pirimoglu B, Bayraktutan U, *et al.*: **Herlyn-Werner-Wunderlich syndrome: a very rare urogenital anomaly in a teenage girl.** *J. Emerg. Med.* 2015; **48**(3): e73–e75.  
[PubMed Abstract](#) | [Publisher Full Text](#)
15. Grimbizis GF, Camus M, Tarlatzis BC, *et al.*: **Clinical implications of uterine malformations and hysteroscopic treatment results.** *Hum. Reprod. Update.* 2001; **7**(2): 161–174.  
[PubMed Abstract](#) | [Publisher Full Text](#)
16. Venetis CA, Papadopoulos SP, Campo R, *et al.*: **Clinical implications of congenital uterine anomalies: a meta-analysis of comparative studies.** *RBM Online.* 2014; **29**(6): 665–683.  
[PubMed Abstract](#) | [Publisher Full Text](#)
17. Heinonen PK: **Reproductive performance of women with uterine anomalies after abdominal or hysteroscopic myomectomy or no surgical treatment.** *J. Am. Assoc. Gynecol. Laparosc.* 1997; **4**(3): 311–317.  
[Publisher Full Text](#)
18. Othman M: **Uterine Didelphys Pregnancy Management.** *J. Adv. Med. Med. Res.* 2018; **26**: 1–5.  
[Publisher Full Text](#)
19. Lin PC, Bhatnagar KP, Nettleton GS, *et al.*: **Female genital anomalies affecting reproduction.** *Fertil. Steril.* 2002; **78**(5): 899–915.  
[Publisher Full Text](#)

UNIVERSITY OF IBADAN LIBRARY

# Open Peer Review

Current Peer Review Status: 

---

## Version 1

Reviewer Report 05 September 2022

<https://doi.org/10.5256/f1000research.135217.r144392>

© 2022 Akinfolarin A. This is an open access peer review report distributed under the terms of the [Creative Commons Attribution License](#), which permits unrestricted use, distribution, and reproduction in any medium, provided the original work is properly cited.



### Adepiti Clement Akinfolarin

Department of Obstetrics, Gynecology, and Perinatology, The Obafemi Awolowo University, Ile-Ife, Nigeria

This is a succinctly described case report. It touched essentially on the presentation, examination, diagnosis and treatment. The description and discussion are detailed and have added to the body of knowledge on the subject of MDA.

However, one is not convinced that in a didelphic uterus, which is usually smaller than normal uterus, an average sized fetus in cephalic presentation at 37 weeks would spontaneously convert to breech at 38 weeks. What is the cadre of the personnel that performed that examination at 37 weeks?

Essentially, its a good case report.

**Is the background of the case's history and progression described in sufficient detail?**

Yes

**Are enough details provided of any physical examination and diagnostic tests, treatment given and outcomes?**

Yes

**Is sufficient discussion included of the importance of the findings and their relevance to future understanding of disease processes, diagnosis or treatment?**

Yes

**Is the case presented with sufficient detail to be useful for other practitioners?**

Yes

**Competing Interests:** No competing interests were disclosed.

**Reviewer Expertise:** Gynaecological oncology

**I confirm that I have read this submission and believe that I have an appropriate level of expertise to confirm that it is of an acceptable scientific standard.**

---

The benefits of publishing with F1000Research:

- Your article is published within days, with no editorial bias
- You can publish traditional articles, null/negative results, case reports, data notes and more
- The peer review process is transparent and collaborative
- Your article is indexed in PubMed after passing peer review
- Dedicated customer support at every stage

For pre-submission enquiries, contact [research@f1000.com](mailto:research@f1000.com)

**F1000Research**

UNIVERSITY OF IBADAN LIBRARY