

Ocular gun-shot injuries in Ibadan

A. M. AGBEJA AND O. OSUNTOKUN

Department of Ophthalmology, University College Hospital, Ibadan, Nigeria

Summary

Twenty patients with eye injuries resulting from gun-shots were admitted to the University College Hospital, Ibadan, over a 10-year period. Three of the patients had involvement of both eyes, making a total of 23 eyes. Seven eyes had contusion injuries, while 16 had perforating injuries. Eight of the perforating group had primary evisceration, two refused evisceration and six had repair of corneal/corneo-scleral wounds. All seven eyes in the contusion group were treated conservatively and four retained a vision of better than 6/36. Seven out of the 20 patients were shot by someone else, six of whom were armed robbers. The other 13 patients were shooting animals while hunting, when the gun either backfired or exploded in their faces.

Résumé

Vingt patients qui ont été blessé aux yeux par des balles ont eu l'admission à l'University College Hospital, Ibadan, Nigéria, pendant une période de 10 ans. Trois des patients ont été affecté dans les deux yeux, en faisant le total de 23 yeux. Sept yeux ont eu les blessures de contusion tandis que 16 ont eu les blessures de perforation. On a fait l'éviscération primaire dans huit du groupe de perforation mais deux patients ont refusé l'éviscération et six patients ont eu la réparation des blessures cornées/corneo-sclérotiques. Tous les sept yeux dans le groupe de contusion ont été traité conservativement et quatre ont conservé une vision de meilleur que 6/36. Six de 20 patients ont été tiré par les voleurs armés et le septième par une autre personne. Les autres 13 patients ont été blessé en chassant les animaux.

Correspondence: Dr A. M. Agbeja, Department of Ophthalmology, University College Hospital, Ibadan, Nigeria.

Introduction

Ocular injuries from firearms are commonly due to accidental backfiring of the guns used for hunting game [1]. However, with the increasing wave of armed robbery in Nigeria, more patients are presenting who have been shot by someone else. The ocular injuries associated with gun-shots are usually quite severe, perforation of the globe with retained intra-ocular foreign bodies being the commonest presentation. The injured eye is usually so badly damaged that there is associated loss of sight [1–4].

In this retrospective study, all cases of gun-shot wounds affecting the eye presented to us between 1979 and 1989 were reviewed.

Patients and methods

The clinical records of all patients with gun-shot wounds affecting the eye, admitted to the University College Hospital, Ibadan, between 1979 and 1989 were reviewed. Special attention was paid to the type of ocular injury, treatment, final best corrected vision, type of gun used and whether the patient was the one shooting or was shot at.

Results

Twenty patients with ocular gun-shot injuries presented to this department between 1979 and 1989. Three of the patients had both eyes affected. In each of these three patients, one eye was perforated and the other eye had contusion injury; 19 of the patients were males and only one was female. The age range was 10–65 years with an average age of 37 years. The main findings are shown in Tables 1 and 2, which have been divided into perforating injuries (16 eyes) and contusion injuries (seven

Table 1. Patients with perforating injuries

Case no.	Sex/age	Eye injury	Management	Visual acuity		Type of gun	Cause of injury
				Initial	Final		
1.	M/50	Left perforation	Evisceration	NPL	NPL	Shot-gun	Shot at
2.	F/45	Left double perforation	Evisceration	NPL	NPL	Shot-gun	Shot at
3.	M/36	Right double perforation	Evisceration	NPL	NPL	Dane	Shooting
4.	M/55	Right perforation	Wound sutured	NPL	NPL	Dane	Shooting
5.	M/60	Right ruptured globe	Evisceration	LP	NPL	Dane	Shooting
6.	M/45	Left perforation	Refused evisceration	NPL	NPL	Dane	Shooting
7.	M/50	Left perforation	Wound sutured	6/12	6/24	Dane	Shooting
8.	M/30	Right perforation	Refused evisceration	NPL	NPL	Dane	Shooting
9.	M/37	Right perforation	Wound sutured & removal of IOFB	HM	6/36	Dane	Shooting
10.	M/30	Left perforation	Wound sutured & removal of IOFB	NPL	NPL	Dane	Shooting
11.	M/43	Right perforation & cataract	Wound sutured	HM	NPL	Dane	Shooting
12.	M/30	Right ruptured globe	Evisceration	NPL	NPL	Dane	Shooting
13.	M/41	Right ruptured globe	Evisceration	NPL	NPL	Dane	Shooting
14.	M/10	Right perforation	Wound sutured & removal of IOFB	NPL	NPL	Dane	Shot at
15.	M/65	Left ruptured globe	Evisceration	NPL	NPL	Dane	Shooting
16.	M/45	Right perforation	Evisceration	LP	NPL	Dane	Shooting

IOFB = intra-ocular foreign body; NPL = no perception of light; LP = light perception; HM = hand movement.

Table 2. Patients with contusion injuries

Case no.	Sex/age	Eye injury	Management	Visual acuity		Type of gun	Cause of injury
				Initial	Final		
1.	M/50	Right cataract, vitreous haemorrhage	Conservative	HM	CF	Shot-gun	Shot at
2.	F/45	Right conjunctival congestions, chemosis	Conservative	6/12	6/4	Shot-gun	Shot at
3.	M/55	Left multiple corneal abrasions, sub-conjunctival pellets	Pellets removed	HM	6/24	Dane	Shooting
4.	M/55	Right vitreous haemorrhage, commotio retinae	Conservative	LP	NPL	Shot-gun	Shot at
5.	M/47	Right vitreous haemorrhage, dislocated lens	Conservative	NPL	NPL	Dane	Shooting
6.	M/22	Right vitreous hemorrhage, sub-conjunctival pellets	Pellets removed	6/24	6/4	Shot-gun	Shot at
7.	M/31	Left vitreous haemorrhage, commotio retinae	Conservative	6/60	6/24	Shot-gun	Shot at

HM = hand movement; CF = counting fingers; LP = light perception; NPL = no perception of light.

eyes). The seven eyes with contusion injuries were all managed conservatively, i.e. no surgical treatment was given to the eyeball, although two patients with subconjunctival pellets had these removed. Four retained a vision of better than 6/36, two had no light perception and one had counting fingers.

Of the 16 eyes with perforating injuries, seven had retained intra-ocular foreign bodies, four had the pellets in their orbits, one had the pellet embedded under conjunctiva and one had the cap of the pellets embedded in the zygomatic region of the face (Fig. 1). In three eyes, the pellets were nowhere to be found. X-ray pictures of some of these patients showed different sites of the pellets (Figs 1-4). Four of the 16 perforated eyes had total rupture of the globe with loss of intra-ocular contents, and the evisceration was thus completed surgically. All four eyes were hit by the cap of the pellet compartment of the gun which shot back into their eyes as they were shooting. The size of these caps ranged from 20 to 30 mm in length. Eight of the 16 perforated eyes had evisceration as the primary surgical procedure, two refused evisceration, the eyes eventually becoming phthisical, and six had repair of corneal and/or scleral wounds, with removal of retained intra-ocular foreign bodies. Foreign bodies in the

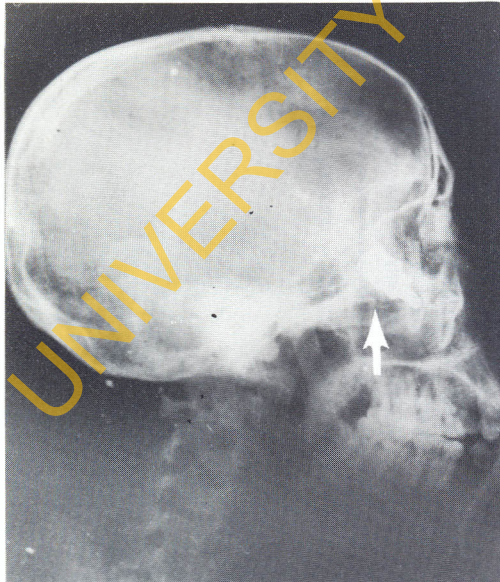

Fig. 1. X-ray picture of a cap in the zygomatic region.

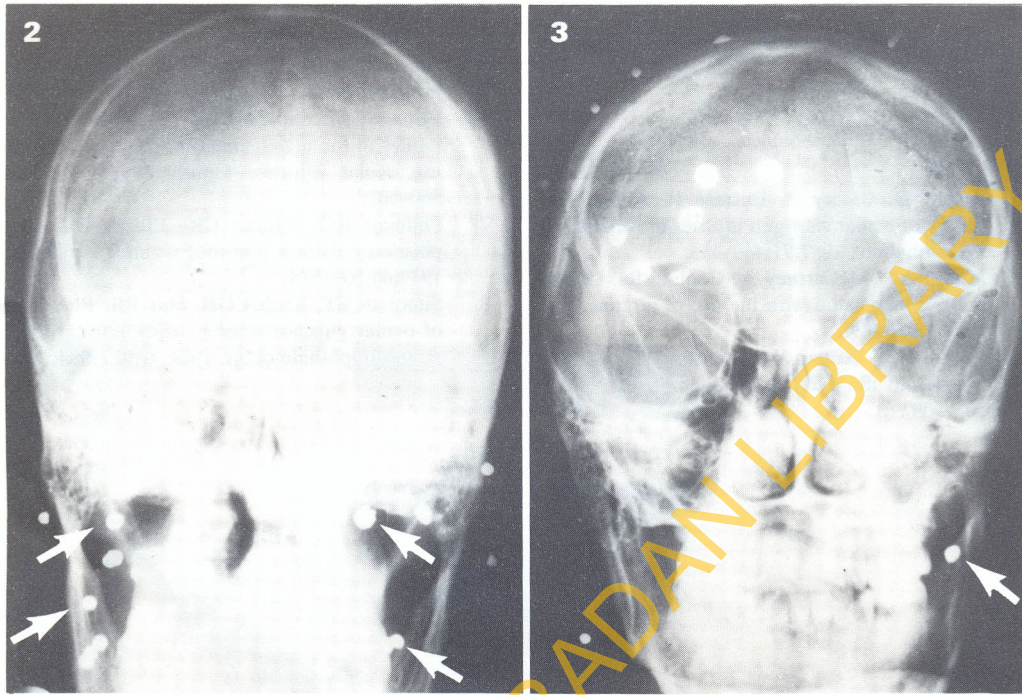
orbit were left alone but the pellet cap embedded in the zygomatic region was removed surgically. Visual outcome in the perforated group was poor, 11 out of the 16 eyes (69%) ended up with a vision of no perception of light, two with perception of light only, two with hand movement and only one had a vision of 6/12 corrected.

Out of the 20 patients, 13 were shooting while hunting game and seven were shot at, six by armed robbers and one, a 10-year-old boy, was accidentally shot by his brother while hunting. All 13 patients who were shooting were making use of dane-guns, while the six attacked by armed robbers were attacked with shot-guns; the 10-year-old boy was shot with a dane-gun.

Discussion

Accidental ocular gun-shot injuries are a regular occurrence during the shooting season [2], but in our study 30% of the patients were shot by armed robbers; 95% of the patients were males, as most hunters are males, the only woman in the study was shot by an armed robber. Eye injuries caused by missiles from guns are usually quite severe, with poor visual prognosis [5]. In 87% of the patients in this study, vision was reduced to 6/60 or less in the injured eye, and in 34.8% the extent of the injury, with accompanying endophthalmitis, caused by retained intraocular foreign bodies, necessitated evisceration.

The most severe injuries were found in the penetrating injury group, in which only two of the 16 eyes involved retained useful vision, most of the others having had evisceration. None of the contusion group required evisceration. The others in the perforating injury group who did not require evisceration had surgical repair of the entry wound with removal of any intra-ocular foreign body. Various studies have described extensively the surgical management of these cases [1,2,6]. Contusion injuries were treated conservatively, although there is a risk of late retinal detachment. The visual prognosis in these cases was good, four out of seven eyes (57%) retaining a visual acuity of 6/36 or better. In the cases where the patients were shooting game, 69% had the right eye involved. This was found to be due to the fact that most hunters



Figs 2 & 3. X-ray pictures of pellets scattered all over the face including both orbits.

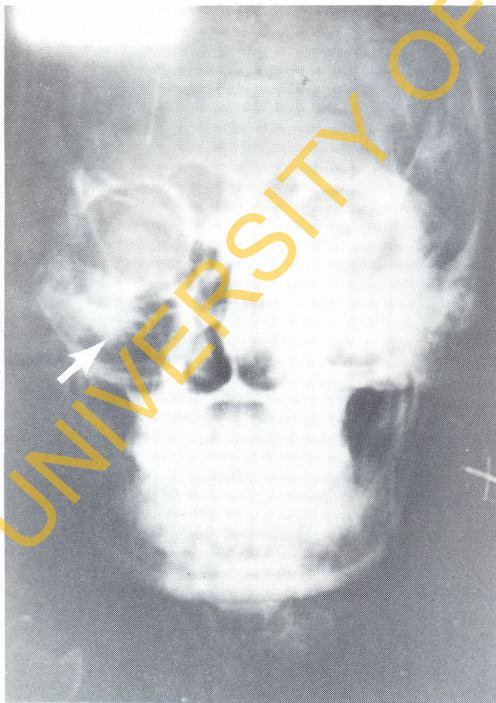

Fig. 4. X-ray picture of a cap in the orbit.

focus on animals with the right eye while trying to shoot, while the left eye is kept closed for a no-parallax view between the gun and animal. In the contusion groups 71.5% of the patients were shot at, all by armed robbers. In this group, the cause of the contusion may be due to the fact that the gun being fired was at a distance from the patient, unlike the patients who were shooting, in whom the backfiring gun was right next to their faces.

Plain X-rays of the orbit have been found to best locate retained pellets with the use of a limbal ring to locate the position in or around the eye. In this study, the pellet was retained in the eye and orbit in 12 patients (60%). Dane-gun pellets have a high lead content and so present a potential risk of systemic lead poisoning [7].

In conclusion, there should be more public awareness about the dangers of these weapons and various safety precautions that could be taken. Hunters should be advised to wear safety goggles. In a previous study, safety glasses incorporating polycarbonate lenses were found to withstand the impact of airgun pellets [8].

These could be tried on some hunters, as the visual prognosis after ocular gun-shot injuries is poor [5].

References

1. Roden D, Cleary P, Eustace P. A five-year survey of ocular shot-gun injuries in Ireland. *Br J Ophthalmol* 1987;71:449-453.
2. Moore AT, McCartney A, Cooling RJ. Ocular injuries associated with the use of airguns. *Eye* 1987;1:422-429.
3. Brown GC, Tasman WS, Benson WE. BB-gun injuries to the eye. *Ophthalmic Surg* 1985;16:505-508.
4. Kreshon MJ. Eye injuries due to BB-guns. *Ophthalmology* 1964;58:858-861.
5. Edmund J. The prognosis of perforating eye injuries. *Acta Ophthalmol* 1968;46:1165-1174.
6. Conway BP, Michels RG. Vitrectomy techniques in the management of selected penetrating ocular injuries. *Ophthalmology* 1978;85:560-563.
7. Dillman RO, Crumb CK, Lidsky MJ. Lead poisoning from a gun-shot wound. *Am J Med* 1979;66:509-514.
8. Simmons ST, Krohel GB, Hay PB. Prevention of ocular gunshot injuries using polycarbonate lenses. *Ophthalmology* 1984;91:977-984.

(Accepted 19 March 1990)

UNIVERSITY OF IBADAN LIBRARY