

Rigid retrograde endoscopy under regional anaesthesia: a novel technique for the early realignment of traumatic posterior urethral disruption

EO Olapade-Olaopa, SA Adebayo, OM Atalabi*, AA Popoola, IA Ogunmodede, and UF Enabulele

Division of Urology, Department of Surgery and *Department of Radiology, College of Medicine, University College Hospital, University of Ibadan, Ibadan, Nigeria.

Summary

Traumatic disruption of the posterior urethra usually occurs in association with pelvic fractures and may result in significant morbidity. The management of this injury remains difficult and controversial. Recently, early restoration of urethral continuity in these patients using either both antegrade and retrograde cystoscopy (with or without fluoroscopy), or flexible retrograde urethroscopy alone under general anaesthesia, has been reported with good results. These procedures have been proposed as an improvement over the traditional teaching of placement of a suprapubic catheter followed by delayed open repair (urethroplasty). We now describe a novel method of restoration of urethral continuity by rigid retrograde endoscopy alone under caudal anaesthesia in the early post-trauma phase. This procedure can be carried out in an outpatient endoscopic suite with standard (endoscopic) optical urethrotomy equipment and is suitable for most patients with prostatomembranous urethral disruptions. A 'high-riding' prostate is however a relative contraindication for this procedure. To date, we have carried out this procedure successfully in 4 of 5 patients with traumatic prostato-membranous disruption (a success rate of 80%). We recommend that early retrograde rigid endoscopic realignment under regional analgesia should be considered as a management option in patients with traumatic disruption of the posterior urethra.

Keywords: Urethral trauma, urethral realignment, pelvic fractures, regional anaesthesia, endoscopy.

Résumé

La perturbation traumatique de l'urètre postérieur a lieu très souvent en association avec les fractures pelviennes et peut résulter d'une morbidité significative. La gestion de cette blessure est difficile et très contestée. Récemment la restauration de la continuité urétrale chez ces patients utilisant soit la cystoscopie étrograde/postgrade (avec ou sans fluoroscopie), soit l'urethroscopie rétrograde flexible seulement sous anesthésie générale, a été reportée avec succès. Ces procédures ont été proposées comme amélioration de l'enseignement traditionnel basé sur le placement du tube de drainage suprapubique suivi d'un réparation ouverte retardée (urethroplastie). Nous décrivons maintenant une nouvelle méthode de restauration urétrale continue par endoscope rétrograde rigide seulement, sous anesthésie locale dès les premières phases post-traumatiques. Cette procédure peut être pratiquée dans une salle endoscopique avec des équipements d'urethrotomie optique standard (endoscopique) et va bien chez la plupart des patients

avec des perturbations prostatomembraneuses urétrales. Une prostate à 'fonction-élevée' est cependant une contre-indication relative de cette procédure. Jusqu'à nos jours, nous avons appliqué cette procédure sur 4 des 5 patients ayant un traumatisme prostatomembraneux (un succès de 80%). Nous recommandons que le realignement endoscopique rétrograde rigide sous anesthésie régionale/locale pourrait être considéré comme option de gestion chez les patients ayant des perturbations traumatiques de l'urètre postérieur

Introduction

Traumatic disruption of the posterior male urethra usually occurs in association with fractures of the pelvis [1]. Although the traditional method of managing this injury (the insertion of a suprapubic catheter followed by a delayed repair [urethroplasty] after an interval of 6-12 weeks) is usually successful, it presents significant additional morbidity and can be technically challenging [2, 3]. Endourological urethral repair was first described by Towler and Eisen in 1987 [4], followed by modifications of the technique for delayed [5, 6] and early primary realignment of the ruptured urethra [7, 8]. These procedures have recorded a high success rate (90%) but require general anaesthesia and employ either, both antegrade and retrograde (rigid or flexible) cystoscopy, or fluoroscopy and retrograde endoscopy (see reference No. 7 for a detailed description). In a further modification of the technique, Klieb et al reported their success in realigning traumatic posterior urethral disruptions using retrograde flexible cystoscopy only under general anaesthesia in 100% (4 of 4) and 50% (2 of 4) of their patients with partial and complete transactions respectively [9].

A high stricture rate (50-100% [5-9]) is associated with endoscopic repair of the ruptured prostato-membranous urethra. However as the avulsed urethral ends are brought in close proximity by the urethral stenting (with a catheter), these strictures are short and most are easily treated with dilatation and/or direct vision internal urethrotomies. Furthermore, endourological urethral realignment does not preclude a formal urethroplasty for those strictures that are refractory to endoscopic treatment (due to length or recurrence).

We now describe a modified method of early endoscopic realignment of a disrupted posterior urethra by rigid retrograde urethro-cystoscopy alone (without antegrade assistance) under caudal anaesthesia. We believe that this technique is a further improvement over the previously described methods, and that it is particularly well suited to two centers in developing nations which often have no access to fluoroscopy and limited modern endoscopic equipment available.

Technique of management

Diagnosis and pre-operative management

Following presentation with a suspected traumatic urethral injury (blood at the meatus and acute retention in a patient with perineal

Correspondence: Mr E. Oluwabunmi Olapade-Olaopa, Division of Urology, Department of Surgery, College of Medicine, University College Hospital, The University of Ibadan, PMB 5116, Ibadan, Nigeria. e-mail: okeoffa@yahoo.com

or pelvic trauma), standard management protocols for trauma patients should be instituted in the Accident and Emergency Department. Plain x-rays should be done to confirm or exclude pelvic fractures in all patients. A digital rectal examination must be done to determine if the prostate is 'high-riding', indicating disruption of the pubo-prostatic ligaments (a relative exclusion criteria for this procedure – see 'Discussion' section). An emergency suprapubic cystostomy should be done to relieve urinary retention.

In patients in whom other more serious injuries have been excluded or treated, a retrograde urethrogram should be done (preferably within 48-72hrs post-injury) to identify the site of urethral injury. Patients in whom disruption of the posterior urethra is confirmed should then be consented and the procedure scheduled to be done between 4 and 14 days following the injury. If major pelvic fractures are found, orthopaedic opinion should be sought (if available) as regards placement of the patient in the moderate lithotomy position required for the operation.

Procedure

Under antibiotic cover, and regional anesthesia (caudal anaesthesia and instillation of xylocaine gel) the patient is placed in the lithotomy position. An intravenous dose of a sedative/anxiolytic (e.g., Temazepam or Diazepam 5mg) is also given. Similar to earlier reports, we were able to place our patients with pelvic fractures in a moderate lithotomy position without added morbidity [7]. A Sache Optical urethrotome (along with a catheterising sheath) is inserted into the urethra and passed down to the site of the urethral disruption. There is usually no active bleeding at the trauma site at this time but the urethral lumen may be partly occluded by a flimsy membranous scar tissue leaving a variable sized opening. A flexible-tip guide wire is passed into the opening in the scar tissue for a few centimeters. A gentle direct vision optical urethrotomy is then done (preferably at 12 and 6 o'clock only) along-side the guide-wire, taking care to incise only the scar tissue and not the normal urethral tissue to avoid extending the length of the traumatized urethra and provoking renewed bleeding. This is achieved by gently cutting forwards into the scar and not backwards in the standard urethrotomy manner. This maneuver will allow passage of the urethrotome beyond the urethral tear into the trauma cavity that usually comprises of coagulated blood and disrupted peri-urethral tissue. The cavity is then inspected carefully for the proximal end of the disrupted urethra (which is usually displaced somewhat superiorly and laterally). Once identified, the guide wire is then inserted through the proximal end of the urethra and into the bladder, and the urethrotome (along with the catheterising sheath) passed over it into the bladder. The urethrotome is withdrawn leaving the catheterising sheath in place through which a well lubricated size 16Fr self-retaining catheter is inserted into the bladder and left on free drainage. The catheterising sheath is withdrawn and the suprapubic catheter spigotted.

Post-operative management

The patient is then returned to the ward and discharged either to the Orthopaedic Surgeons for management of his pelvic fractures or sent home a few days after his surgery with both catheters in-situ. A peri-catheter RUG is done at 6 weeks to confirm healing of the disrupted site and the urethral catheter removed. A micturating cysto-urethrogram (MCUG) is then done through the suprapubic catheter prior to its removal to evaluate the caliber of the urethra at the healed trauma site.

Illustrative cases

We have carried out this procedure successfully in 4 of 5 patients with traumatic prostatico-membranous disruption (a success rate of 80%) at the time of writing this report. Two of these cases are presented below, an index case of success and the only failure in our series.

Case 1

A 28 year-old male presented to our Hospital with a suspected pelvic fracture following a pedestrian road traffic accident (RTA). He was unable to urinate necessitating an emergency suprapubic cystostomy to relieve his retention. His prostate was normally placed on rectal examination. Plain x-ray of the pelvis confirmed moderately displaced bilateral fractures of the superior and inferior pubic rami with symphyseal diastasis. Subsequent retrograde urethrogram showed complete urethral disruption of the prostatico-membranous urethra with extravasation of contrast (Fig.1).

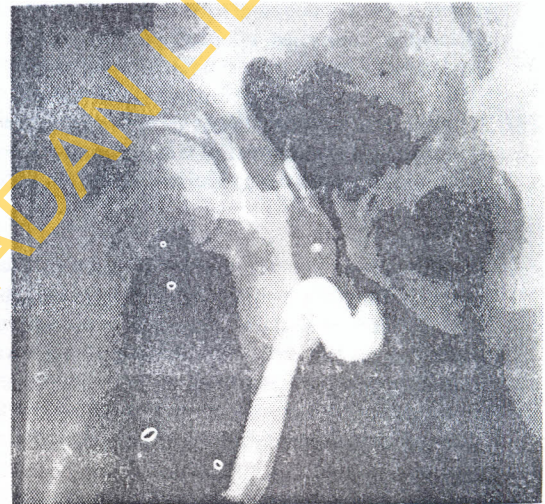

Fig. 1: Radiograph of a pre-operative retrograde urethrogram done 3 days after presentation in a patient who was admitted with acute urinary retention and blood at the meatus following a road traffic accident. The study shows abrupt cessation of contrast flow in a posterior urethra with intravasation of the contrast into the pelvic vessels in keeping with a traumatic posterior urethral disruption. Note bilateral fractures of the superior and inferior pubic rami

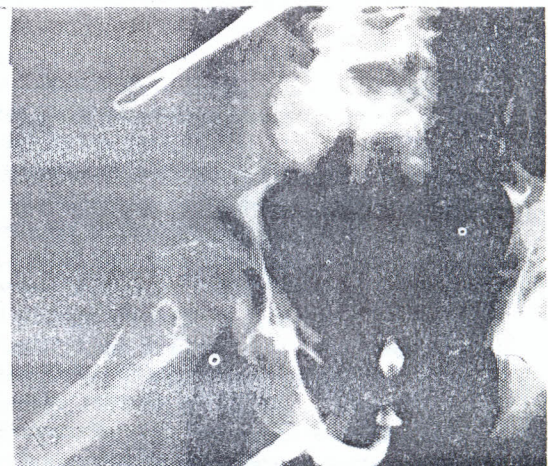


Fig. 2: Radiograph of a post-operative peri-catheter retrograde urethrogram done six weeks after early rigid retrograde urethral realignment in the patient shown in Figure 1. This shows no extravasation of contrast which flows up to the bladder neck thus confirming restoration of urethral continuity and healing of the disrupted urethra.

He was scheduled for primary endoscopic realignment of the urethra under sedo-analgesia in our outpatient endoscopy suite 11 days after his injury. At surgery he had complete urethral disruption with a 1cm gap between both ends. This was successfully realigned by retrograde rigid endoscopy as described above. The suprapubic catheter (SPC) was spigotted and left in-situ. A retrograde urethrogram was done six weeks after the procedure that showed no extravasation of contrast indicating healing of the urethra (Fig. 2). The urethral catheter was removed and a micturating cystourethrogram (MCUG) was done to confirm urethral healing and exclude stricture formation (Fig. 3). He voided successfully and was continent. The SPC was removed. And he was sent home to be reviewed again in the Surgical Outpatient Clinic.

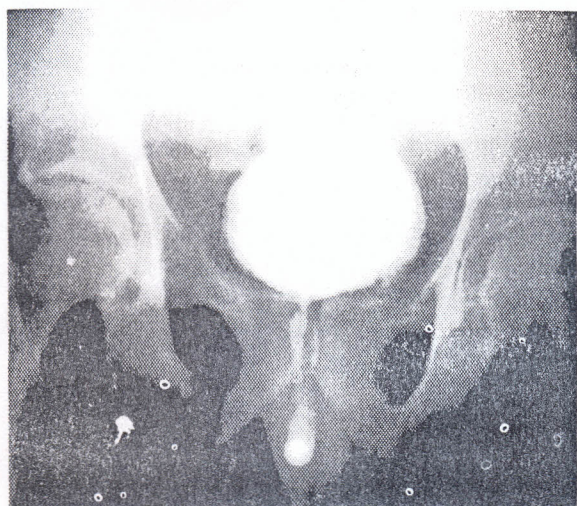


Fig. 3: Radiograph of a micturating cysto-urethrogram following removal of the urethral catheter in the same patient. This shows free flow of contrast in a normal caliber posterior urethra.

Case 2

A 32 year-old male was transferred to our Hospital with a diagnosis of pelvic fractures and urethral injury 2 days after being involved in an RTA. He had been unable to void immediately after the accident and an emergency suprapubic cystostomy had been done. Rectal examination revealed a 'high-riding' prostate. Plain x-ray of the pelvis confirmed bilateral mildly displaced fractures of the superior and inferior pubic rami with no symphyseal diastasis. Complete posterior urethral disruption was confirmed on retrograde urethrography. Two attempts at primary retrograde endoscopic realignment of the urethral disruption on days 8 (under local anaesthesia) and 11 (under general anaesthesia) were however abandoned due to the inability to locate the proximal end of the torn urethral in the large (>2.5cm) trauma cavity. He was therefore scheduled for a delayed open urethroplasty and is currently awaiting this procedure.

Discussion

Our technique of early primary realignment via rigid retrograde endoscopy alone under regional analgesia for prostatomembranous urethral disruptions is novel as we are unable to find previous reports of a similar technique in medical literature. The recent report from Stuart Wolf's group at the University of Michigan described a similar technique but using the flexible cystoscope under general anaesthesia [9]. It is important to note that our technique also obviates the need for antegrade endoscopy and fluoroscopy and this is an advantage particularly in developing countries where these procedures are

largely unavailable. This method is therefore most likely to be successful in patients with short disruptions (i.e., <1.5cm as in *Case 1* below), but not in cases with longer gaps between the urethral ends as the large trauma cavity would make it particularly difficult to locate the proximal end of the transected urethral (see *Case 2*). Accordingly, patients with a 'high-riding' prostate (i.e. marked posterior displacement resulting from disruption of the pubo-prostatic ligaments and/or the urogenital diaphragm), or bladder neck injuries (Goldman Urethral Injury Type III-IV [10]) should be considered for the traditional method of management. In addition, the use of regional anaesthesia ensures that the procedure can be done in the outpatient endoscopy suite instead of main operating theatres. This is a major advantage when the limited theatre time in most (developing) countries and the reduction in costs are considered.

We believe that when urethral realignment is achieved by this new technique, satisfactory long-term results similar to the antegrade assisted endoscopic techniques can be expected. In addition, as damage to the uninjured urethra is further minimized in our technique, we expect a lower stricture rate than realised the earlier series but the patients should however be warned of the potential need for additional endoscopic procedures to treat those (strictures) that occur. Furthermore, similar to the older endoscopic technique, our method does not preclude a formal urethroplasty should endoscopic treatment of the strictures fail. We continue to carry out this procedure in our Institution and shall be publishing our series in due course.

Conclusion

Early primary retrograde endoscopic realignment of the traumatic ruptured urethra under regional analgesia is a safe, rapid and non-traumatic technique. We believe that this novel procedure is a valuable addition to the Urologist's repertoire of methods of urethral repair. In particular, the establishment of urethral continuity shortly after the injury offers the chance of avoiding the additional morbidity of delayed urethroplasty.

Acknowledgements

The authors would like to express their sincere gratitude to Dr Okeke, Mr Shittu and the Nursing Staff of the University College Hospital Surgical Outpatient Clinic for their support during the development of this technique. We would also like to express our sincere appreciation of the assistance of the Medical Illustration Department, College of Medicine, University of Ibadan, Ibadan in preparing the illustrations.

References:

1. Morchouse, D, P.Belitsky, and K.MacKinnon, Rupture of the posterior urethra. *Journal of Urology*, 1972. 107: p. 255-258.
2. Lieberman, S. and J. Barry, Retreat from transpubic urethroplasty for obliterated membranous urethral strictures. *Journal of Urology*, 1982. 128: p. 379-381.
3. Koraitim, M. Pelvic fracture urethral injuries: evaluation of various methods of management. *Journal of Urology*, 1996. 156: p. 1288-1291.
4. Towler, J and S. Eisen, A new technique for the management of urethral injuries. *British Journal of Urology*, 1987. 60: p. 162-166.
5. Gonzalez, R., *et al.* Endoscopic re-establishment of urethral continuity after traumatic disruption of the membranous urethra. *Journal of Urology*, 183. 130: p. 785-787.
6. White, J, Hirsch,I and D. Bagley, Endoscopic

- urethroplasty of posterior urethral avulsion. *Urology*, 1994. 44: p. 100-105.
7. Jepson, B., *et al.* Traumatic posterior urethral injury and early primary endoscopic realignment: evaluation of long-term follow-up. *Urology*, 1999. 53: p. 1205-1210.
 8. Moudouni, S, *et al.*, Early endoscopic realignment of post-traumatic posterior urethral disruption. *Urology*, 2001. 57: p. 628-632.
 9. Kielb, S, Z. Voeltz, and J.W Jr, Evaluation and management of traumatic posterior urethral disruption with flexible cystoscopy. *Journal of Trauma*, 2001. 50: p. 36-40.
 10. Goldman, S., *et al.* Blunt urethral trauma: a unified, anatomical mechanical classification. *Journal of Urology*, 1997. 157: p. 85-89.

UNIVERSITY OF IBADAN LIBRARY