

Hunter syndrome: Case report and review of literature

*Adebola Ogunbiyi¹, A. O. Adeyinka², S. O. Ogah¹ and A. M. Baiyeroroju³

Departments of ¹Medicine, ²Radiology and ³Ophthalmology,
University College Hospital, Ibadan.

Summary

Hunter syndrome is one of the mucopolysaccharidosis, which are a rare group of genetic diseases. It is due to a deficiency in the enzyme Iduronate 2-sulphatase. This in turn leads to the accumulation of glycosaminoglycans, dermatan and heparan sulphate. The intra and extracellular accumulation of this substances lead to multisystemic organ abnormality. We present a patient with Hunter syndrome who presented with involvement of the skin, cardiovascular system, the eyes and musculoskeletal system. We have also included a literature review. As far as we know, it is the first case reported in a Nigerian.

Key-words: *Hunter syndrome, Complications, Nigerian.*

Résumé

Le syndrome du chasseur est l'un de la mucopolysaccharidose, qui sont un groupe rare des maladies génétiques. Il est attribuable à la carence de l'enzyme Iduronate 2-sulfate. Ceci encore provoque une accumulation de glycosaminoglycans, dermatan et sulfate d'heparin. L'accumulation de l'intra et extracellulaire de ce matières provoquent un organe multisystémique anormal. Nous présentons un patient atteint du syndrome de chasseur impliquant la peau système cardiovasculaire, des yeux et système musculosquelettique. Nous avons aussi écrit le compte rendu. Autant que nous sachons, il s'agit d'un premier cas rapporté au Nigeria.

Introduction

Hunter syndrome is one of the mucopolysaccharidosis, (MPS) which are a rare group of genetic diseases, resulting from defects in various lysosomal enzymes, which break down mucopolysaccharides. These defects lead to accumulation of glycosaminoglycans in various organs. Individuals affected have a striking appearance, and are referred to as 'gargoyles'.²

There are about thirteen different clinical syndromes of MPS.² We report a case of Hunter syndrome, as far as we know this is the first reported case in a Nigerian.

Case report

A 14-year-old boy was seen in the dermatology clinic with complaints of 'bumps' on his head and some rash on his back. His mother claimed that he had been a normal child at birth. However, at the age of 6 years, she noticed a rash on the upper back and some bumps on his scalp, which were slowly increasing in size. She also felt he looked different from her other 3 children who were well. She had visited various health care facilities without any improvement.

On further questioning he had tiredness on exertion, which had been progressive in the last 2 years and difficulty with seeing at night, which was worse in the last 6 months.



Fig. 1 shows large head, peri-orbital oedema, flat nose and thick lips




Fig. 2 Pebbly appearance of the skin, characteristic of Hunter syndrome.

There was no other significant past medical history. He was the second of 4 children. All other siblings were well. There is no family history of a similar problem. Mother claimed no member of her family had presented with a similar problem. The patient is presently in the third year in the secondary school and appears to be doing well.

Clinical examination revealed a young boy with short stature, height 1.2 meters. He had a large head with coarse facial features, bilateral peri-orbital oedema, flat nose, thick lips and a large tongue (Fig. 1). He had about six firm painless nodules about 1cm in diameter, on the scalp. He also had a protuberant abdomen.

* Correspondence

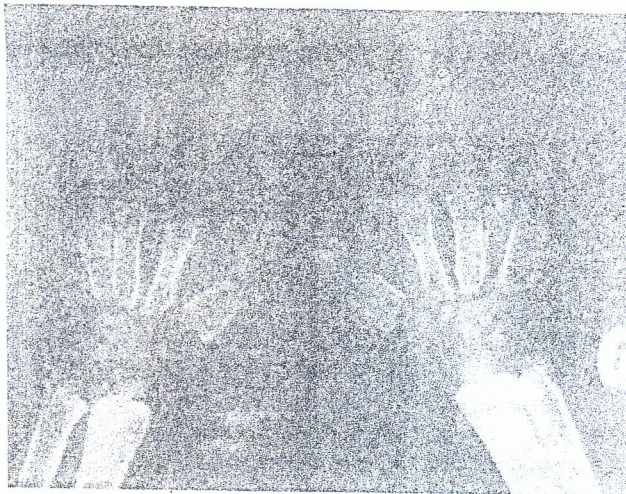


Fig. 3 Plain radiograph of both hands showing coarse trabeculae with widened metacarpal shafts and narrowing or tapering of their proximal ends.




Fig. 4 Plain radiographs of the lumbosacral spine showing oval shaped vertebrae with anterior-inferior beaking of T12 and L1.

Cardiovascular assessment was essentially normal except for an apical systolic murmur (grade 3/6). An echocardiogram showed a bifid aortic valve and mild regurgitation of both mitral and aortic valves. The musculo-skeletal system revealed, claw like hands and stiff joints in the extremities.

Skin examination revealed a thickened and inelastic skin especially in the extremities. There were skin colored papules arranged in ridges symmetrically between the angles of the scapulae and posterior axillary lines (Fig 2). He also had acanthosis nigricans on the neck and axilla and fine hair on most of the trunk. Other significant findings were in the abdomen, he had an umbilical hernia and hepatosplenomegaly.

Ophthalmologic examination revealed a visual acuity of 6/5 in both eyes unaided. He had bilateral mechanical ptosis due to marked fullness of both orbits especially the upper lids. Anterior segments of both eyes were quiet and his

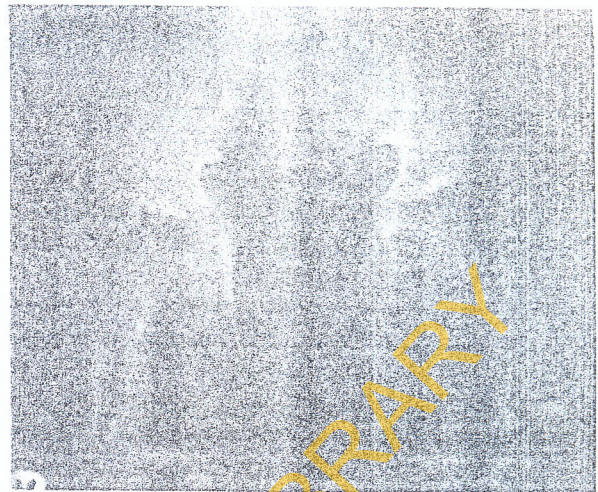


Fig. 5 Plain radiograph of the iliac bone showing an unusual tapering towards the acetabula with fusion of the sacro-iliac joint. The acetabula fossae bilaterally is sclerosed and shallow with irregular protuberances.

corneas were clear, there was no evidence of corneal clouding. His intraocular pressures were 18mmHg (Right) and 22mmHg (left). Pupils reacted to light and accommodation and there was no relative papillary afferent defect. The lenses were clear. Fundoscopy revealed mildly pale waxy looking discs with blurred margins, the cup/disc ratio was 0.3 in both eyes, the vessels were attenuated and the maculae looked normal. There were scattered bone speckled pigmentary deposits in the mid-peripheral retina along blood vessels, typical of retinitis pigmentosa. He was advised to stay indoors at night.

Radiological investigations showed a thickened skull vault with parietal protuberance bilaterally with a dolicocephalic shape. The pituitary fossa was within normal limits. X-rays of the hands revealed coarse bony trabeculations. The metacarpal shafts were wide with narrowing or tapering of the proximal ends, (Fig. 3). The lumbosacral spine showed oval vertebrae with antero-inferior breaking of T12 and L1 (Fig 4). There is widening of the interperpendicular spaces, while the disc spaces are normal. The iliac bones bilaterally show an unusual tapering towards the acetabula with fusion of the sacro-iliac joint. The acetabula fossae bilaterally are sclerosed, shallow with irregular protuberances (Fig. 5).

A haematological work up and thyroid function test were normal. Urinalysis was also normal. Urine was not tested for glycosamines. A skin biopsy done showed widely separated collagen bundles in the dermis. The epidermis was normal; there were paucity of adnexal structures in the dermis, accumulation of mucin within the stroma suggestive of mucopolysaccharidosis.

Discussion

Hunter syndrome, type II MPS was first described by Charles Hunter in 1917.³ It is inherited as sex-linked recessive and most patients are males. Females are carriers, although a few cases of females with the syndrome have been reported.⁴

It is caused by a deficiency in the activity of the lysosomal enzyme exohydrolase iduronate-2-sulphatase located at Xq28.⁵ A number of mutations in the X-chromosomal human iduronate-2-sulphatase gene have now been identified. The mutations described include various deletions, splice-site, and point mutations.⁶ The enzyme deficiency leads to intracellular and extra cellular accumulation of glycosaminoglycan, dermatan and heparan sulphate.⁷

The accumulation of glycosaminoglycans in the various tissues leads to organomegaly, skeletal deformities, neurodegeneration and coarsening of facial features. Most patients with mucopolysaccharidosis have a characteristic appearance, which led to the term 'gargoyles.' They have large heads, large tongues and usually have a short stature with a protuberant abdomen.

There are 2 main types of Hunter syndrome, a severe type A associated with neurodegeneration leading to mental retardation, dysostosis multiplex and death before the age of fifteen years as a result of cardiac or respiratory difficulties. The mild form is associated with normal intelligence, skeletal and cutaneous abnormalities and survival to adult hood. Other intermediate forms of the syndrome exist which can be explained by the varied mutations that occur. We feel our patient may have a mild form of the disease. Although the syndrome is uncommon world wide, a higher incidence has been reported amongst Jews in Israel.⁸ There are very few reports of the syndrome in blacks, especially Africans (Personal observation).

Children with Hunter syndrome are normal at birth. Symptoms appear as early as 2 years in the severe form and before the age of 10 years in the mild form as was the case in our patient.

Cutaneous features are peculiar to this syndrome and may be the initial manifestation in the mild form of disease although patients in both groups may have skin involvement.⁹ The skin findings also help to distinguish this syndrome from other MPSs.

Firm skin colored papules, 2-10cm in diameter and nodules (pebbles) coalesce to form ridges or a reticular pattern and occur in symmetrical areas between the angles of the scapular and posterior axillary lines. These lesions could also be found on the lateral aspects of the upper limbs, or the nape of the neck. The pebbles tend to occur before the age of 10 years, as was the case in our patient. These pebbles are found mainly in Hunter syndrome^{5,10,11} and helps in differentiating it from other MPS. Generalised hypertrichosis also occurs in most patients with MPS.

Cardiovascular complications are common in patients with Hunter syndrome. These include incompetence of the valves on the left side of the heart, mitral valve prolapse, ischaemic heart disease and cardiomegaly resulting in heart failure.^{12,13} Respiratory problems in these patients are not uncommon. This is due to deposition of glycosaminoglycans in soft tissue leading to airway obstruction at various levels. Chronic respiratory failure and obstructive sleep apnoea syndrome occur commonly.^{14,15}

Neurological complications in these patients include hydrocephalus and pseudotumor cerebri.¹⁶ Carpal tunnel syndrome appears to be a common problem¹⁷ in affected chil-

dren. Excellent reviews of oral complications, in these patients have been documented.¹⁸ The musculoskeletal complications include claw shaped hands and stiff joints. Other musculoskeletal deformities picked up by radiological investigations are documented below.

The radiological manifestations of Hunter's and Hurler's syndromes (MPS I) are similar.¹⁹ The imaging features of the extremities are usually varied with the upper limb more affected than the lower limbs. The long bones are usually sclerotic and thickened at the shaft with tapering towards the end. An increased angulated obliquity of the growth end plates with the radius and ulna tipped towards each other may be evident. The most characteristic appearance is the proximal tapering of the metacarpals as seen in this case report. Coxa valga of the femoral head with genu valgum is constantly present in the lower limbs. Larger skull with dolicocephalic shape has been reported. Prominence of the frontal bone with "J shaped" sella turcica may also be present.¹⁹ Only the dolicocephalic shape and prominence of the parietal bone were noticed in our patient. Radiological examination of the mandible and dentition were not carried out.

Varied imaging features may also be present in the spine and pelvis. These include anterior inferior beaking of the lumbar vertebrae, occasional vertebrae hypoplasia with angular kyphosis.¹⁹ Hypoplasia and demineralization of the pedicles and widening of the interpedicular spaces with or without posterior vertebrae scalloping are common radiological features. Fanning of the iliac wings and tapering of the ilia near the acetabulum are the usual bone pelvic changes. The acetabulum may also be shallow as reported in this case report. Other abnormalities include widened rib shafts with a spatula like "narrow origin and bullet nose."¹⁹ Appearance of the termination resulting in a "canoe paddle" rib.¹⁹

Ophthalmological complications are common in patients with MPS. Corneal clouding is absent in patients with Hunter syndrome and this helps to distinguish it from the other mucopolysaccharidosis. Retinitis pigmentosa, elevated and blurred disc margins leading to chronic papilloedema and optic atrophy have all been documented.^{20,21} Our patient's nocturnal blindness was due to the retinitis pigmentosa.

Diagnosis is suspected clinically but may be delayed in the mild forms. Steps in diagnosis include examination of urine for dermatan and heparan sulphate especially in advanced cases.²²

Biopsy of the skin papules may show cutaneous mucinosis consistent with mucopolysaccharidosis.²³ Metachromatotic granules may be seen within dermal fibroblast and within collagen fibres. Accumulated MPS may be seen in the sweat gland or other cells in the skin.

Where diagnosis is not clear enzyme level in fibroblast or white blood cells could be measured. Level of enzyme deficiency found is not synonymous to clinical severity of the illness. There is no cure presently for Hunter syndrome so medical care is directed towards relieving symptoms. Monitoring of the cardiovascular and respiratory systems is important. Pre-natal testing is also available for children at risk.⁷

Where possible, haematopoietic stem cell transplant or

enzyme replacement therapy could be carried out.^{24, 25} Reports have shown reversal of skin changes, hepato splenomegaly and cardiovascular complications after the transplant in children.^{26, 27} However skeletal changes are irreversible. Bone marrow transplantation within the first few months of life is advocated where possible.

References

1. Muenzer J, Lamsa J C, Garcia A, Dacosta J, Garcia J, Treco D A. Enzyme replacement therapy in mucopolysaccharidosis type II (Hunter syndrome): a preliminary report. *Acta Paediatr Suppl.* 2002; 91: 98 - 9.
2. Black M M, Gawkrödger D J, Seymour et al. Metabolic and nutritional disorders. Vol 4. In Rook, Wilkinson and Ebling Eds. *Textbook of Dermatology*, 5th Ed. Oxford Blackwell Scientific publications, London Edinburgh Boston. 2239 - 2381.
3. Hunter C. Rare diseases in two brothers *R soc Med.* 1917; 10: 104 - 116.
4. Curdy S, Tigaud I, Froissart R, et al. MPS II in females: molecular basis of two different cases. *J Med Genetics* 2000; 37: 29.
5. Neufeld E, Muenzer J. The mucopolysaccharidosis. In: Scriver C, Beaudt A, Sly W, et al, Eds. *The molecular and inherited basis of genetic diseases*, Vol 3, 8 Ed. New York: McGraw-Hill, 2000: 3421 - 3437.
6. Hill L P, Bellow A B, Thompson J N. Molecular basis of iduronate 2-sulphatase gene mutations in patients with mucopolysaccharidosis type II (Hunter syndrome) *J Med Genet.* 1999; 36: 21 - 7.
7. Wapper R S. Lysosomal storage disorders. In: McMillan J, DeAngelis C, Feigin R, Warshaw J, Eds. *Oski's paediatrics: principles and practice*, 3rd ed. Philadelphia: Lippincott, 1999; 1869 - 1872.
8. Ben-Simon-Schiff E, Ziotogora J, Abeliovich D, et al. Hunter syndrome among Jews in Israel. *Bio Med Pharmacother* 1994; 48: 381 - 4.
9. Demistsu T, Kakurai M, Okubo Y, et al. Skin eruption as the presenting sign of Hunter syndrome IIB. *Clin Exp. Dermatol.* 1999; 24: 179 - 82.
10. Prystowsky S D, Maumenee I H, Freeman G et al. A cutaneous marker in the Hunter syndrome. *Arch Derm* 1977; 113: 602 - 605.
11. Cole H N, Irving R C, Lund H Z et al. Gargoylism with cutaneous manifestations, *Arch Dermatol* 1952; 66: 371 - 382.
12. Sonino V, Sekarski N, Matthieu M, Payout M. Mitral valve prolapse and type II mucopolysaccharidosis. Report of two familial cases. *Arch Mal Coeur vaiss* 2001; 94: 518 - 22.
13. Wraith J E. The mucopolysaccharidosis: a clinical review and guide to management. *Arch Dis Child* 1995; 72: 263 - 267.
14. Shih S L, Lee Y J, Lin S P, et al. Airway changes in children with mucopolysaccharidosis. *Acta Radiol* 2002.
15. Orliquet O, Pepin J L, Veale D, et al. Hunter syndrome and associated sleep apnea cured by CPAP and surgery. *Eur Respir J* 1999; 13: 1195 - 7.
16. Sheridan M, Johnston I. Hydrocephalus and psuedotumor cerebri in the mucopolysaccharidosis. *Childs Nerv Syst* 1914; 10: 148 - 50.
17. Bona I, Vial C, Brunet P, et al. Carpal tunnel syndrome in mucopolysaccharidosis. A report of four cases in a child. *Electromyogr Clin Neurophysiol* 1994; 34: 471 - 5.
18. Downs A T, Crisp J, Ferrette G. Hunter syndrome and Oral manifestations: a review: *Pediatr Dent.* 1995; 17: 98 - 100.
19. Chen S J, Li Y W, Wang T R, Hsu J C. Bone changes in common mucopolysaccharidosis.
20. Danis P, Toussant D. Retinal pigmentary changes in mucopolysaccharidosis of the Hunter type. *Bull Soc Belge Ophthalmol* 1971; 157: 365 - 73.
21. The cornea in systemic disease in Thomas D. *Duane's clinical ophthalmology.* Harper and Row publishers, Philadelphia Pg. 23 - 30.
22. Thappa D, Singh A, Jaisankar T, et al. Pebbling of the skin: a marker of Hunter syndrome. *Pediatr Dermatol* 1998; 15: 370-373.
23. Freeman R G. A pathological basis for the cutaneous papules of mucopolysaccharidosis II (the Hunter syndrome). *J cutan Pathol* 1977; 4: 318 - 320.
24. Ito K, Ochiai T, Suzuki H. hHe effect of haematopoietic stem cell transplant on papules with pebbly appearance in Hunter syndrome. *Br J Dermatol* 2004; 152: 207 - 11.
25. Kakkis E, Muenzer J, Tiller G, et al. Enzyme - replacement therapy in mucopolysaccharidosis I. *N Engl J Med* 2001; 344: 182 - 188.
26. Coppa G V, Gabriella O, Zampini I, et al. Bone marrow transplantation in Hunter syndrome (mucopolysaccharidosis type II): two-year follow-up of the first Italian patient and review of the literature. *Pediatr Med Chir.* 1995 May-Jun; 17: 227 - 35.
27. Joly H, Dauphin C, Motreff P, Die Rberolles C, Lusson J R. Double aortic and mitral valve replacement in an 18year old patient with Hunter's disease. *Arch Mal Coeur Vaiss.* 2004; 97: 561 - 3.