

## ORIGINAL ARTICLE

AFRICAN JOURNAL OF CLINICAL AND EXPERIMENTAL MICROBIOLOGY. JANUARY 2014 ISBN 1595-689X VOL15 No.1  
AJCEM/1322 <http://www.ajol.info/journals/ajcem>  
COPYRIGHT 2014 <http://dx.doi.org/10.4314/ajcem.v15i1.2>  
AFR. J. CLN. EXPER. MICROBIOL. 15(1): 9-13

# MOLLUSCUM CONTAGIOSUM VIRUS INFECTION AMONGST PLWHA IN IBADAN, NIGERIA

<sup>1</sup>Fayemiwo, S.A.,<sup>2</sup>Adesina, O.A., <sup>3</sup>Akinyemi, J.O., <sup>4</sup>Odaibo G.N., <sup>5</sup>Omikunle, T.O. and <sup>2</sup>Adewole, I.F.

<sup>1</sup>Departments of Medical Microbiology & Parasitology, <sup>2</sup>Obstetrics & Gynaecology, <sup>3</sup>Epidemiology and Medical statistics and <sup>4</sup>Virology, University of Ibadan, Ibadan, Nigeria, <sup>5</sup> Department of Family Medicine, University College Hospital, Ibadan, Nigeria.

RUNNING TITLE: *MOLLUSCUM CONTAGIOSUM* VIRUS INFECTION IN IBADAN, NIGERIA.

\* Correspondence: Dr. Fayemiwo, S.A., Department of Medical Microbiology & Parasitology, College of Medicine, University of Ibadan & University College Hospital, Ibadan. E-mail address: [dayteet@yahoo.com](mailto:dayteet@yahoo.com)

## ABSTRACT

**Background:** *Molluscum contagiosum* (MC) infection is caused by a pox virus and the virus is probably passed on by direct skin-to-skin contact which may affect any part of the body. There is anecdotal evidence associating facial lesions with HIV-related immunodeficiency. This study was aimed to determine the prevalence and associated risk factors of *Molluscum contagiosum* infection among PLWHAs attending ART clinic at the University College Hospital, Ibadan, Nigeria. **Methods:** This is a descriptive cross-sectional survey of 5,207 patients (3519 female and 1688 males) attending ART clinic between January 2006 and December 2007. Physicians performed complete physical and pelvic examinations. Diagnosis of *Molluscum Contagiosum* infection was based on the clinical findings of typical lesions on the external genitalia, perianal, trunk, abdominal and facial regions. **Results:** The mean age of the patients was 34.67 yrs.  $\pm$  9.16). About 10% (542) had various sexually transmitted infections (STIs). The male to female ratio was 1: 4.2. One hundred and twenty seven subjects (23.4%) had no formal or primary education with 247 (45.6 %) being treatment naïve while 295 (54.4 %) were treatment experienced. Of the 542 PLWHAs with STIs, 3.3 % had undetectable viral load (< 200 copies/ml) while 272 (50.1 %) had low CD<sub>4</sub> count (< 200 cells/mm<sup>3</sup>) and The Mean log<sub>10</sub> viral load was 5.02  $\pm$  0.94. *Molluscum Contagiosum* infection was diagnosed in 13 patients (0.024%; 8 females and 5 males). Vaginal Candidiasis was the commonest genital infection diagnosed in 223 (41.1%) of the patients with STIs. MC patients had higher viral load, lower CD4 count and more likely to be treatment experienced. **Conclusions:** *Molluscum Contagiosum* infection is not uncommon among the HIV-infected patients, but underreported. Awareness of this cutaneous manifestation should be known to Physicians in AIDS care.

**Key Words:** *Molluscum contagiosum*, HIV, Sexually Transmitted Infection

## INTRODUCTION

*Molluscum contagiosum virus* (MCV) infection is a disorder of the skin and mucous membranes, characterized by discrete, single or multiple, flesh-colored papules. It was first described by Bateman in 1817 (1). MCV infection is caused by up to four closely-related types of pox virus, MCV-1 to MCV-4 and their variants (2). In small children, virtually all infections are caused by MCV-1; whereas in patients infected with HIV, MCV-2 causes the majority (60 %) of infections, suggesting that HIV infection-associated Molluscum does not represent recrudescence of childhood Molluscum (3). Epidemiologic studies also suggest that transmission may be related to factors

such as warmth and humidity of the climate and poor hygiene (4).

Although, transmission of Mollusci poxvirus in children is thought to occur by intimate skin-to-skin contact or through fomites, in adults, MC is most often sexually transmitted and is being increasingly diagnosed in the sexually active population. *Molluscum contagiosum* virus infection occurs worldwide but is more prevalent in tropical areas (5). The infection is most common in children, sexually active adults, and persons with impaired cellular immunity, particularly HIV-positive patients. MC has a worldwide incidence of between 2-8%. Between 5- 20% of HIV patients have MC infection. The incubation period for MC has been reported to be

between 14 and 50 days, although there are reports of newborns having lesions as early as 7 days post-partum (6). An individual infected with *Molluscum contagiosum* virus can also spread the infection via autoinoculation. The virus infects epidermal keratinocytes and viral replication occurs in the cytoplasm of these cells(7).

The typical lesion is a smooth-surfaced, firm, spherical papule; with an average diameter of 3-5 mm. Giant lesions of up to 1.5 cm have been described and are seen more often in immunocompromised patients. Lesions may be flesh colored or translucent white or light yellow in color. The number of lesions is usually less than 30, but as many as several hundred may be seen. Up to 100 lesions may coalesce to form a plaque. The most distinctive feature of MCV infection is the central umbilication.

It has been recognized for sometime that MC is a common cutaneous disorder seen in patients with HIV infection. The association was first reported in 1983 when it was noted in an autopsy study that two of ten patients with Acquired Immune Deficiency Syndrome (AIDS) had lesions of MCV. In contrast to HIV seronegative adults, in whom MCV lesions are usually genital, lesions in HIV individuals most often involve the face, neck, and trunk. Because this distribution is similar to that seen in children, in whom the spread is thought to occur through fomites or casual contact, transmission in HIV infected patients does not appear to be solely by sexual contact(8).

Patients with advanced HIV disease often have persistent Molluscum lesions that gradually increase in size, with some patients developing giant, tumor-like, nodular lesions that can exceed 1 cm in diameter and become very deforming(8-10). The number of lesions generally varies inversely with CD4 cell count, with some patients with very advanced immune suppression developing several hundred lesions in a disseminated pattern(10).

There is paucity of data on the burden of *Molluscum contagiosum* viral infection among adult PLWHA in Nigeria. This study was aimed at providing information on prevalence of *Molluscum contagiosum* infection among PLWHAs attending ART clinic, University College Hospital, Ibadan, Nigeria.

## METHODS AND PATIENTS

This was a descriptive cross-sectional survey of 5,207 patients attending ART clinic between January 2006 and December 2007.

For each patient, the demographic data, brief complaints, site of lesion, morphology, progression of the disease, family history, sexual history, and risk factors for HIV infection were noted. Physicians performed complete physical and pelvic examinations for signs of sexually transmitted infections (STIs).

Initial diagnosis of *Molluscum Contagiosum* viral infection was based on the clinical findings of typical multiple, painless dome-shaped lesions with characteristic central umbilication on any of the following areas: the external genitalia, perianal, trunk, abdominal and facial regions(Figure 1-3). This was followed by the expression of the thick white core from the center of the lesions which was then smeared and stained with Giemsa stain on a slide to reveal Molluscum bodies. The diagnosis was confirmed with hematoxylin-eosin staining of the skin biopsy from the subjects. Histology of the skin biopsies showed the presence of large, eosinophilic, intracytoplasmic Henderson-Patterson inclusion bodies (Figure 4).(11) The urethral, high vaginal and endocervical swabs were taken and processed by standard microbiological methods(12) from each of the subjects to establish diagnosis of other STIs.

## Data Analysis

Data was analyzed using SPSS (Inc, Chicago, IL) version 15 software for windows. Association between groups was performed using the chi-square test for categorical variables and student-t test for continuous variables and statistical tests were carried out at 5 % significance level.

## RESULTS

A total of 5,207 patients, 3519 female and 1688 males attended the ARV clinic during the period. The mean age of the patients was 34.67 yrs±9.16). About 10% (542) had various STIs.

The male to female ratio was 1: 4.2. 127 had no formal or primary education, 8.9 % of them were widowed while 9.0 % separated from their spouses. Two hundred and forty-seven of them (45.6 %) were treatment naïve while 295 (54.4 %) were treatment experienced. 27.4% of the 536 PLWHA reported willingness and consistent usage of condom. 3.3 % out of the 542 PLWHAs with STIs, had undetectable viral load (< 200 copies/ ml) while 272 (50.1 %) had low CD<sub>4</sub> count (< 200 cells / mm<sup>3</sup>.) and The Mean log viral load was 5.02 ± 0.94.

The prevalence of *Molluscum Contagiosum* infection was 0.024 % ( 8 female and 5male ). 10-20 Molluscum contagiosum lesions were seen in 6 cases, followed by

less than 10 in 3 cases, 20-30 lesions in 2 cases, and more than 40 lesions in 2 cases. Vulvo-vaginal Candidiasis was the commonest genital infection diagnosed in 223 (41.1%) of those screened.

Higher risky sexual behavior was found to be significantly associated with low level of education ( $P < 0.0001$ ) while treatment-experienced patients

were more likely to use of condom (Table 1). Other inflammatory genital infections diagnosed were; genital warts-(35.0%), bacterial vaginosis (27.1%), trichomoniasis (10.0 %) and tinea cruris (0.5%).

MC patients had higher viral load, low CD4 count (mean-85 cells/mm<sup>3</sup>) and more likely to be treatment experienced.

TABLE 1: ODD RATIO FOR TREATMENT STATUS AND CONDOM USE

Treatment Status	CONDOM USE : Yes	CONDOM USE : No	TOTAL	OR ( 95% CI )
Naïve	37 (15.4%)	204 (84.6%)	241(45.0%)	3.28 (2.15-5.00 )
Experienced	110 (37.3%)	185 (62.7%)	295 (55.0%)	
TOTAL	147 (27.4%)	389 (73.6%)	536	

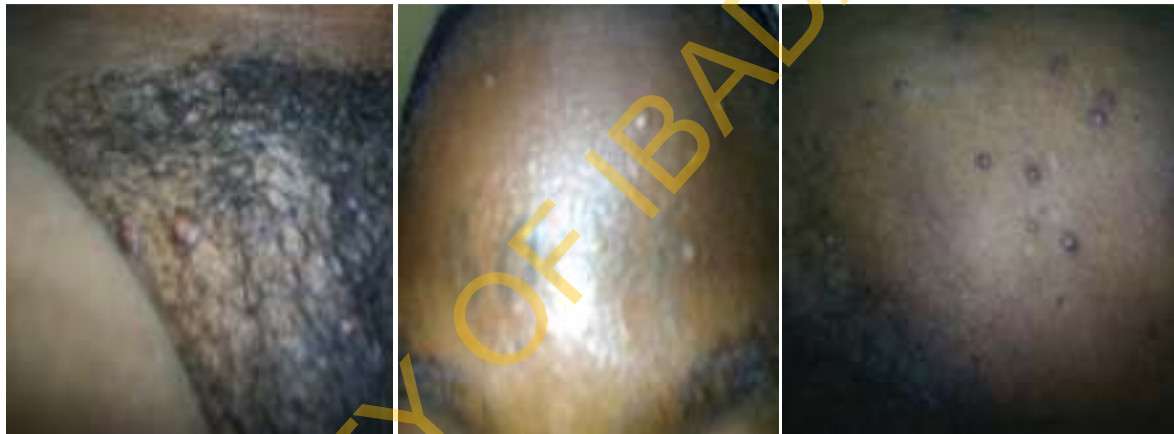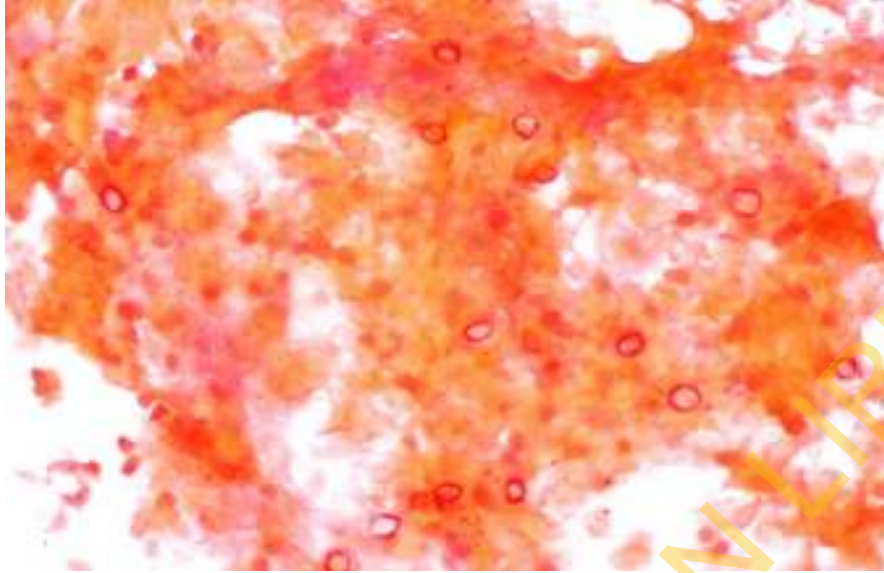


Figure 1: Genital Molluscum contagiosum Lesion

Figure 2 : Facial Molluscum Contagiosum lesion

Figure 3: Abdominal Molluscum

The prevalence of *Molluscum contagiosum* was 2.0 times higher in patients with higher Viral Load (Mean Log - 1.97), lower CD4 Count (Mean - 85 Cells/mm<sup>3</sup>), treatment experienced compared to treatment naïve patients.



**Fig 4: Photomicrograph of skin scrapings showing molluscum bodies**

## DISCUSSION

Although the exact incidence of *Molluscum contagiosum* (MC) infection in HIV-infected persons remains unknown, studies have estimated that 5 to 18% of untreated HIV-infected patients develop the Lesions during their clinical course(13). In our study, the prevalence of MC lesions was 0.024%. This was found to be quite low compared to what was obtained in other studies with similar group of patients(14-16).

MC is a self-limiting disease which if left untreated, will eventually resolve in immunocompetent hosts, though it may be protracted in atopic and immunocompromised individuals. Among HIV-infected patients who develop *Molluscum contagiosum*, most have advanced immune suppression. This was confirmed in our study that showed a mean CD4 count of approximately 85 cells/mm<sup>3</sup> among the patients with MC infection. Our finding was also supported by other studies that established that MC tends to affect more advanced stage HIV-positive patients and with low CD4+ levels(10, 12-14).Overall, compared with immune competent persons, Molluscum lesions in HIV-infected persons with advance immune suppression are characterized by greater number, larger size, more rapid growth, and atypical locations (8,10).

In adult patients with HIV infection, facial and multiple-site presentations are common in many patients. There was no significant difference in the

appearance or location of lesions in immunosuppressed versus healthy patients. It was also found that clinical presentation of aggressive, disseminated and atypical MC lesions (giant or verrucous) are more common in HIV-positive patients(17,18). In our study, the most common sites of involvement are the genitals, head and neck. Widespread facial lesions, and those persisting with a poor response to treatment, are highly characteristic of late HIV disease. Eyelid Molluscum lesions may also be the initial manifestation of AIDS.

One of the most common, quick, and efficient methods of treatment is Cryotherapy. Liquid nitrogen, dry ice, or Frigiderm are applied to each individual lesion for a few seconds. Repeat treatments at 2-3 week intervals may be required.

An easy method to remove the lesions is by eviscerating the core with an instrument such as a scalpel, sharp tooth pick, the edge of a glass slide, or any other instrument capable of removing the umbilicated core. Because of its simplicity, patients, parents, and caregivers may be taught this method so that new lesions can be treated at home.

## Conclusion

Low CD4 cell counts have been linked to widespread facial Mollusca and therefore have become a marker for severe HIV disease. MC associated infection is morecommon among the HIV-infected patients, but

underreported. Awareness of this cutaneous manifestation should be known to Physicians in AIDS care.

### Acknowledgement

The Authors wish to thank and acknowledge the contributions of all Physicians, Counselors, Data staff and Study participants.

### REFERENCE

1. Bateman F. *Molluscum contagiosum* In: Shelley WB, Crissey JT, editors. Classics in dermatology. Charles C Thomas: Springfield (IL); 1953. p. 20.
2. Nakamura J, Muraki Y, Yamada M, Hatano Y, Nii S. Analysis of *Molluscum contagiosum* virus genomes isolated in Japan. J Med Virol. 1995 Aug; 46(4):339-48. [PubMed](#)
3. Odom R.B., James, W.D, Berger, T. G. Andrews' Diseases of the Skin-Clinical Dermatology, 9th Edn. Philadelphia: WB Saunders Company 2000; 501-503.
4. Postlethwaite R. Review Molluscum contagiosum. Arch Environ Health. September 1970; 21(3):432-52. [Arch Environ Health. 1970]
5. Diven DG. An overview of poxviruses. J Am Acad Dermatology. 2001 Jan; 44(1):1-16.
6. Parr RP, Burnett JW, Garon CF. Structural characterization of the molluscum contagiosum virus genome. Virology 1977; 81:247-56.
7. Smith KJ, Yeager J, Skelton H. Molluscum contagiosum: its clinical, histopathologic, and immunohistochemical spectrum. Int J Dermatol. 1999; 38:664-72.
8. Schwartz J.J., Myskowski P.L. Molluscum contagiosum in patients with human immunodeficiency virus infection. J Am Acad Dermatol 1992; 27:583-8.
9. Fayemiwo SA, Odaibo GN, Oni AA, Ajayi AA, Bakare RA and Olaleye DO. Genital ulcer diseases among HIV-infected female commercial sex workers in Ibadan, Nigeria. Afr J Med Med Sci 2011; 40:39-46.
10. Mijušković, Z, KandolfSekulović, L, Zečević, R.D. Molluscum contagiosum and vulval ulceration in HIV infection Serbian Journal of Dermatology and Venereology 2011; 3 (4): 160-164.
11. Smith KJ, Yeager J, Skelton H. Molluscum contagiosum: its clinical, histopathologic, and immunohistochemical spectrum. Int J Dermatol. 1999; 38:664-72.
12. Amsel R, Totten PA, Spiegel, CA, Chen KCS, Eschenbach, D, Holmes, KK. Non Specific Vaginitis: Diagnostic Criteria, microbial and epidemiologic association. American Journal of Medicine 1983, 74; 14-22.
13. Strauss RM, Doyle EL, Mohsen AH, Green ST. Successful treatment of Molluscum contagiosum with topical imiquimod in a severely immunocompromised HIV-positive patient. Int J STD AIDS. 2001; 12:264-6. [[PubMed Abstract](#)]
14. Koopman RJJ, van Merrienboer FC, Vreden SGS, Dolmans WMV. Molluscum contagiosum: a marker for advanced HIV infection. Br J Dermatol 1992; 126:528-9.
15. Schwartz JJ, Myskowski PL. Molluscum contagiosum in patients with human immunodeficiency virus infection. J Am Acad Dermatol 1992; 27:583-8.
16. Bohm M, Luger TA, Bonsmann G. Disseminated giant molluscum contagiosum in a patient with idiopathic CD4+ lymphocytopenia: successful eradication with systemic interferon. Dermatology 2008; 217:196-8.
17. Gur I. The epidemiology of Molluscum contagiosum in HIV seropositive patients: a unique entity or insignificant finding? Int J STD AIDS 2008; 19:503-6.
18. Laxmisha C, Thappa DM, Jaisankar TJ. Clinical profile of *Molluscum contagiosum* in children versus adults. Dermatol Online J 2003; 9:1.