

Pica in Dogs: Overview, Owners Perception and Intestinal Perforative Obstructive Cases in Ibadan, Nigeria

O.D. Eyarefe

Department of Veterinary Surgery and Reproduction, University of Ibadan, Ibadan, Nigeria

Abstract: This study aimed at presenting an overview of pica in dogs, owners' awareness and perception of this obsessive compulsive disorder, the gastrointestinal emergencies and associated surgical risk, with the objective of re-informing and awakening small animal veterinarians to the responsibility of disease prevention through clients' education. Structured questionnaire was administered to dog owners in Ibadan city, Nigeria, to assess the level of their awareness and perception of pica and the health risk the habit poses to dogs. Report of cases of pica managed by the author and associated gastrointestinal surgical emergencies were presented and surgical approach to management discussed. Eighty percent (80%) of dog owners knew that eating of non-food items by dogs could be prevented. Some dog owners (55.7%) agreed that their dogs do sometimes eat non-food items. Some, (72.2%) have taken specific measures to prevent this habit in their dogs, while 66% had discussed with their veterinarian. Many (71.3%) were aware that this behaviour may be associated with deficiency of vital nutrients, while 65.2% were informed that the trait could be associated with anxiety and boredom. Many dog owners (65.3%) have successfully controlled the habit while 55.6% have made efforts at preventing their dogs from eating non-food items. As a result, many of them (59.2%) have provided their dogs with toys to play with while 59.8% constantly prevent their dogs from having access to non-food items. Veterinarians should make effort to educate owners on pica habit and the danger posed by it to pets' health including the financial and psychological stress that pet's ill-health could have on owners.

Key words: Pica • Dog • Owners Awareness • Gastrointestinal Tract Surgical Emergency

INTRODUCTION

Pica (allotriophagia) is a condition of ingestion of non-food materials by animals or human beings [1] and classified under obsessive compulsive disorder (OCD) in both veterinary and human medical literature [2, 3]. Pica is common in humans but relatively less common in animal species. Its aetiology has been associated with trace elements (Zinc, iron, cobalt, phosphorus, etc.) deficiencies, boredom and hunger [2, 4]. Animals, especially dogs, eat various items either deliberately to satisfy need, or inadvertently during play with such items [5]. Some non-nutritional items found in dogs' gastrointestinal tract (GIT) include: sand, stone, metal, forages (grasses), polythene and clothing materials [5-8]. Some of these materials may pass through the GIT without causing obstructive pathology, while others cause severe GIT obstructions and perforations, including

renal, hepatic, metabolic and haemodynamic emergencies [5, 7-10]. Hunt *et al.*, 1991 [7] reported pneumothorax following gastric and diaphragmatic perforations caused by ingestion of foreign materials by dogs. Anuric renal failure associated with zinc intoxication following ingestion of an ornamental brass knob from a toilet paper holder has also been reported [11]. Pica is recurrent among dog breeds as evident by the number and regularity of foreign body obstructive cases reported in literature [5, 8, 12-14]. GIT obstruction caused by ingestion of injurious objects are emergencies associated with high morbidity and mortality rate [12] and in some instances graver when lack of experienced veterinarians and diagnostic facilities hamper quick intervention [15, 16]. The current upsurge in influx of exotic dog breeds prized for their size and resilience into Nigeria; due to security concerns [17] may increase the incidence of pica cases as a result of owner's low level of awareness and

compliance with these exotic dogs' management (Housing and exercise) and nutritional requirements. If pica in dogs and its consequences will be prevented or controlled in Nigeria, owners must be aware and familiar with the health implications of pica traits in their dogs, for them to seek professional assistance for remedy. Currently, there is a dearth of information in literature on dogs' owners' perception and awareness of pica trait in dogs in Nigeria. This study therefore investigated dogs' owners' awareness of pica traits in dogs in Nigeria. Report of recent cases of gastrointestinal obstruction and perforation in dogs managed by the author and associated with pica have been included for emphasis of danger posed to dog's health when pica traits are left unchecked.

MATERIALS AND METHODS

Structured questionnaire was developed and administered to dog owners to survey their perception of pica and possible observation of the trait in their dogs. The questionnaire was pre-tested by few veterinarians and dog owners and based on their comments the questionnaire was modified slightly. The final version consisted of 5 sections which included: Dog and dog owners' demographics; Assessment of owner's experience with dog keeping; Assessment of owner's purpose of dog possession; Assessment of dog's feeding and food supplementation; Dog owner's assessment of dog's attitude to food and non-food items; Assessment of dog owners' knowledge of risk factors for pica. The Likert's scale was adopted as respondent indicator for the study.

Study Location, Instrument Administration and Enrolment Criteria: The questionnaires were administered to exotic dog owners in Ibadan city, the capital of Oyo state, Nigeria with a population of over 3.5 million. Ibadan is the most populous city in the state and the third most populous, in Nigeria, after Lagos and Kano. Ibadan is located in south-western Nigeria, 128 km inland northeast of Lagos and 530 km southwest of Abuja, the federal capital and is a prominent transit point between the coastal region and the areas in the hinterland of the country [18]. Only completely filled questionnaires were used in the analysis.

Data Analysis: Dog owners responses were coded and entered into Microsoft windows excel spread sheet. These were imported into Statistical Package for Social

Sciences (SPSS) Version for windows for further analysis, cross tabulation and regression at 0.05 confidence level. Data generated within each section were presented in percentages with the standard error of means.

RESULTS

110 questionnaires were returned out of 150 questionnaires administered. The respondents (Dog owners) were of ages ten to fifteen years (4.3%), 16-30 years (62.6%), 31-45 years (20.0%) and 45 years and above (8.7%). Eighty percent (80.0%) were males, 14.8% were females while, 5.2% did not indicate their sex. Most of the respondents 42.6% had first degree certificates (Bachelor of Science degree, BSc; Bachelor of Arts, BA or Bachelor of Education, B.Ed.), 20.9% had secondary school leaving certificate, 19.1% had Higher National Diploma (HND), 9.6% had a Master of Science degree or its equivalent while 3.5% had doctorate degree (PhD). A majority (52.2%) had previous experience of dog keeping, 44.3% were keeping dogs for the first time. The respondents had a total of 241 dogs comprising of 15 breeds (Figure 3). Dogs were of ages 1-6 months (28.09%), 7-12 months (9.57%), 1-2 years (28.70%), 3 years and above (28.70%) and unspecified age (6.96%).

Assessment of Purpose for Dog Possession: A significant number of dog owners (96.5%, $p=0.008$) kept their dogs for both security and companionship (Table 1). Such dogs however are also used for breeding by a significant proportion (73.9%, $p=0.000$) of these dog owners.

Assessment of Dogs Feeding and Vitamin/Mineral Supplementation: Many of the dog owners surveyed (80.8%, $p=0.000$) feed their dogs on commercial diet. These dog owners (90.4%) also supplement their dogs' food with home rations. A significant proportion (91.2%, $p=0.000$) supplement dog nutrition with multivitamins/minerals preparations, while 99.1% could describe their dogs' appetite as normal.

Pet Owners' Assessment of Dog's Attitude to Food and Non-Food Items: A majority of the dog owners (55.7%) agreed that their dogs sometimes eat non-food items while 42.6% express a contrary opinion. Many of the dog owners (55.6%) have attempted at one time or the other to prevent their dogs from eating non-food items. Dog owners 65.3% have been able to successfully wean their dogs from eating non-food items.

Table 1: Showing respondents' responses to pica perception

	Strongly Agree	Agree	Disagree	Strongly Disagree	No response	Standard Error of Mean	p	sig (≤ 0.05)
<i>You keep them for companionship alone</i>	34.8	50.4	13.0	0.9	0.9	0.065	.034	S
<i>You keep them for security alone</i>	22.6	51.3	23.5	1.7	0.9	0.069	.154	NS
<i>You keep them for both security and companionship</i>	42.6	53.9	2.6	0	0.9	0.051	.008	S
<i>You keep them for commercial purpose (breeding)</i>	31.3	42.6	22.6	3.5	0	0.077	.082	NS
<i>You feed your dog on commercial dog food</i>	30.4	50.4	15.7	2.6	0.9	0.070	.060	NS
<i>You feed your dog on home formulations</i>	25.2	65.2	7.8	1.7	0	0.058	.092	NS
<i>You feed your dog on waste from canteens</i>	20.9	57.4	13.0	7.0	1.7	0.075	.128	NS
<i>You supplement your dog food with vitamin supplements</i>	32.2	59.0	6.1	0	2.6	0.054	.045	S
<i>Your dog's appetite can be described as "normal"</i>	39.1	60.0	0	0.9	0	0.050	.021	S
<i>Your Pet eats non-food items such as sand, paper, clothing etc</i>	20.0	35.7	32.2	10.4	1.7	0.087	.337	NS
<i>You have attempted to correct your Pet's interest in non-food items</i>	16.5	39.1	31.3	7.0	6.1	0.082	.327	NS
<i>You have been successful in correcting your Pet's interest in non-food items</i>	27.0	38.3	26.1	5.2	3.5	0.083	.144	NS
<i>You are aware that dogs sometimes eat non-food items (PICA)</i>	30.4	55.7	7.0	6.1	0.9	0.073	.051	NS
<i>You have seen a case of PICA in dogs</i>	25.2	55.0	14.8	6.1	0.9	0.076	.094	NS
<i>You are aware that PICA is preventable</i>	22.6	57.4	12.2	7.0	0.9	0.075	.113	NS
<i>You are aware that PICA might be an indication of nutrient deficiency</i>	26.1	45.2	20.9	6.1	1.7	0.080	.104	NS
<i>You are aware that PICA might be an indication of anxiety or frustration</i>	20.0	45.2	27.8	6.1	0.9	0.078	.223	NS
<i>Your Vet has discussed about PICA and its causes with you</i>	21.7	44.3	27.0	6.1	0.9	0.079	.199	NS
<i>You take specific measures to prevent PICA in your dog</i>	17.4	54.8	20.9	6.1	0.9	0.073	.189	NS
<i>You provide your dogs with toys that they can play with</i>	18.3	40.9	33.9	6.1	0.9	0.078	.323	NS
<i>You prevent your dog from having access to non-food items</i>	24.3	38.3	30.4	6.1	0.9	0.082	.225	NS

Key:

p: p value/significance

S: Significant

NS: Not significant

Assessment of Dog Owners Knowledge of the Risk Involved in Eating Non-Food Items: Many of the dog owners surveyed (89.7%, $p < 0.005$) were aware that dogs sometimes eat non-food items; 78.2% ($p < 0.05$) have actually seen dogs with this trait. Many (71.3%) were aware that this behaviour may be associated with deficiency of vital nutrients, while 65.2% were informed that the trait could be associated with anxiety and boredom. Eighty percent (80%) of dog owners knew that eating of non-food items by dogs could be prevented. As a result, 72.2% have taken specific measures to prevent this habit in their dogs, while 66% had discussed with their veterinarian. Many of them (59.2%) have provided their dogs with toys to play with while 59.8% constantly prevent their dogs from having access to non-food items.

Report of Cases

Case Number 1: A 40kg, ten-month-old bullmastiff bitch was referred to the Surgery Clinic of the Veterinary Teaching Hospital, University of Ibadan, with complaint of inappetence of six days duration and frequent vomiting. The owner also complained that a care giver had recently fed the dog with cow bones.

Physical Examination: Rectal temperature at presentation was 39.5°C; heart rate was 64 beats/minute and respiratory rate 48 beats/minute. The stomach appeared full and there was abdominal tenderness on abdominal palpation. Result of blood work showed marked hyperproteinemia and

hyperfibrinogenemia suggestive of clinically significant dehydration. The red cells parameters were within normal limits. The leukogram showed no remarkable deviation from normal limit.

Management: Fluid therapy (Ringer's lactate and later dextrose saline) were administered to correct acid base imbalance and metabolic derangement as well as provide energy.

Diagnostic Imaging: Survey radiograph revealed a lot of gas pockets within bowel lumen with radio opaque substances of bone opacity (Plate 1).

Surgery: Prophylactic antibiotics (Ciprofloxacin and metronidazole infusions) were administered as indicated for bowel surgery. Patient was premedicated with acepromazine (1%, Beruce®, Berk Pharmaceuticals Ltd, England at a dosage of 0.6mg/kg) and tramadol (5%, Tramadex®, Laborate Pharmaceuticals, India at a dosage of 5mg/kg), induced and maintained with pentobarbital Sodium (6%, Kyson prescriptions, South Africa) at a dosage of 10mg/kg for induction and half induction dose for maintenance. The abdomen was accessed via ventral midline laparotomy and bowel segments exteriorized on moist laparotomy sponges as earlier described [19]. Exteriorized bowel showed evidence of palpable bowel foreign body with extensive jejunal segment plication and devitalization. Presence of perforations and peritonitis

were evident (Plate 2). Foreign bodies comprising a large quantity towel material with pieces of bones were removed via enterotomy (Plate 3). The devitalized segment including points of perforations was resected and residual bowel segments anastomosed as earlier described [19].

Case Number 2: A 31 kg, four-year-old boerboele bitch referred to the Surgery clinic of the Veterinary Teaching Hospital, University of Ibadan, with complaint of anorexia of seven days duration and frequent vomiting.

Clinical Examination: Rectal temperature at presentation was 39.9°C, heart rate was 80 beats/minute, pulse rate 75 beats/minute, normal mucous membrane with capillary refill time less than 2 seconds. Plasma protein and fibrinogen, haemoglobin concentration and hematocrit (47%) from result of blood work were within reference values. The leukogram however showed moderate neutrophilia with left shift and severe monocytosis suggestive of an inflammatory process. No parasites were present in wet smear or buffy coat.

Diagnostic Imaging: Abdominal radiograph (Plate 4) shows enlarged bowel segments with gas bubbles and evidence of radio opaque materials within bowel lumen.

Management: Patient was stabilized with fluid therapy (Ringer's lactate and later dextrose saline) to correct acid-base imbalance and metabolic derangement as well as provide energy. Amoxicillin, (Amoxicillin Sodium, non-proprietary, North China Pharmaceutical Co. Ltd, China) 310mg was administered intravenously with metronidazole (Flagyl®, 620mg) at continuous rate via a preplaced catheter.

Surgery: Patient was premedicated with acepromazine (1%, Beruce®, Berk Pharmaceuticals Ltd, England) at a dosage of 0.6mg/kg and tramadol (5%, Tramadex®, Laborate Pharmaceuticals, India) at a dosage of 5mg/kg. Patient was anaesthetized with propofol (was induced and maintained with propofol (1% Diprivan®, ICI Zeneca Pharmaceuticals, UK) at a dosage of 2mg/kg and ketamine (Non-proprietary; Rotexmedia Lab, Trittau Germany) at a dosage of 2mg/kg admixture with half induction dose for maintenance [20]. The abdomen was accessed via ventral midline laparotomy and bowel segments exteriorized on moist laparotomy sponges as earlier described [19]. Exteriorized bowel showed evidence of palpable bowel

foreign body with extensive jejunal segment plication, devitalization and four points of perforations. There was also evidence of peritonitis (Plate 2). A large quantity towel material was removed via enterotomy. The devitalized segment including points of perforations was resected and residual bowel segments anastomosed as earlier described [19].

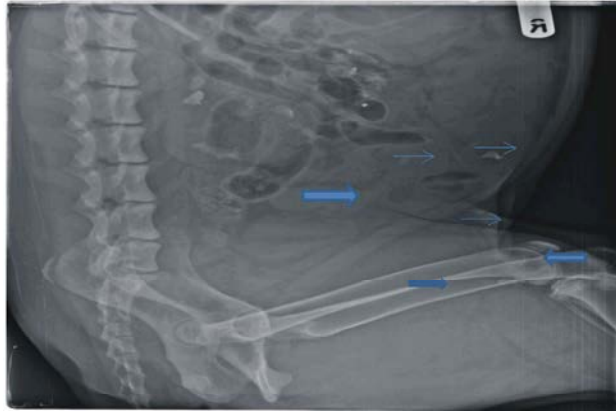
Case Number 3: A seven-year-old intact male German shepherd dog was referred to the Surgery Clinic at the Veterinary Teaching Hospital, University of Ibadan, Nigeria with anorexia of 7 days duration. Animal vomited initially intermittently but later after meals and was emaciated, weak and lethargic.

Clinical Examination: Body weight was 15kg, rectal temperature, 37.7°C. All other vital parameters were within reference values. The presence of a firm mass could be felt on abdominal palpation. Blood sample analysis revealed absence of blood parasites. Haematocrit was 37%. Patient was hyperproteinaemic, leukocytotic with moderate neutrophilia without left shift, mildly lymphopaenic and monocytopenic. All other parameters were within reference values.

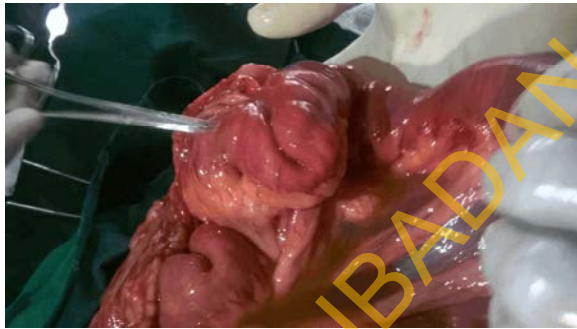
Diagnostic Imaging: Ultrasonography showed a solitary intestinal mass measuring 7.4 by 5.5cm with inconsistent echogenic margin (Plate 5). There was increased peristalsis of the bowels segments. All other abdominal viscera showed normal echo pattern.

Management: Surgery was scheduled following stabilization of the patient with fluid therapy with ringer's lactate to correct acid base imbalance and metabolic derangement and later dextrose saline to provide energy.

Surgery: Ketamine (5% Non-proprietary; Rotexmedia Lab, Trittau Germany) at a dosage of 10mg/kg; xylazine (2 % XYL-M2®, VMD, Belgium) at a dosage of 1mg/kg and tramadol (5%, Tramadex®, Laborate Pharmaceuticals, India) at a dosage of 4mg/kg were administered intramuscularly to achieve balanced anaesthesia, following which the patient was aseptically prepared and laparotomy performed as described for cases 1 and 2 [19]. Exteriorized intestine revealed the presence of an intraluminal foreign body at the upper jejunum (Plate 6), which was found out to be a mango seed following an enterotomy incision made caudal to the foreign body (Plates 7 and 8).



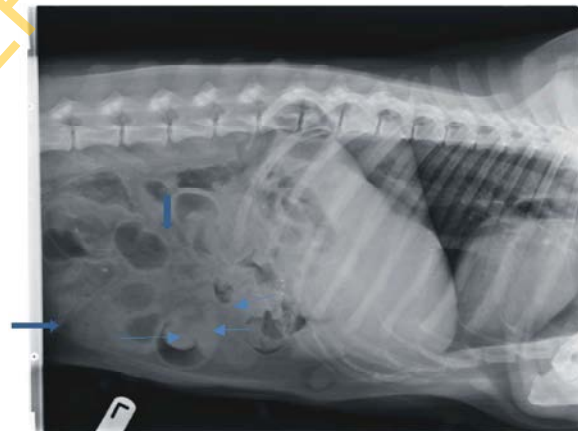Case 1, Plate 1: Right lateral view of radiograph showing gas pocket (Large blue arrows) and materials with bone opacity (Small blue arrows)



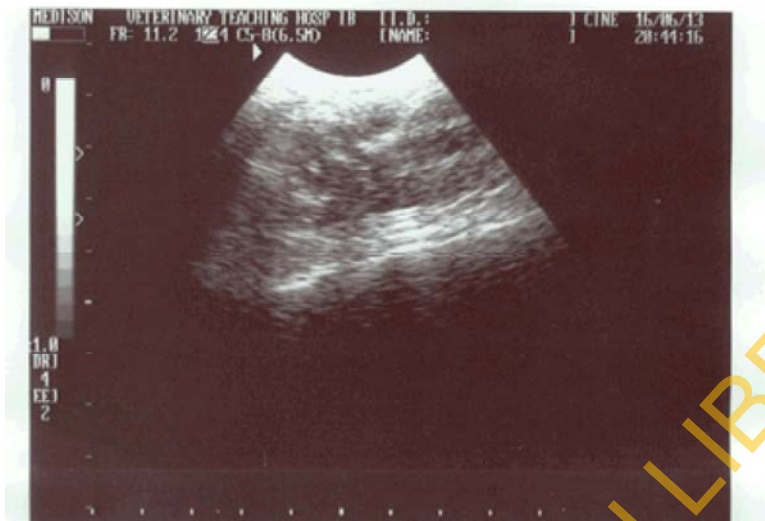Case 1, Plate 2: Showing Bowel perforation (Point of forceps), plication, devitalization of intestinal segments



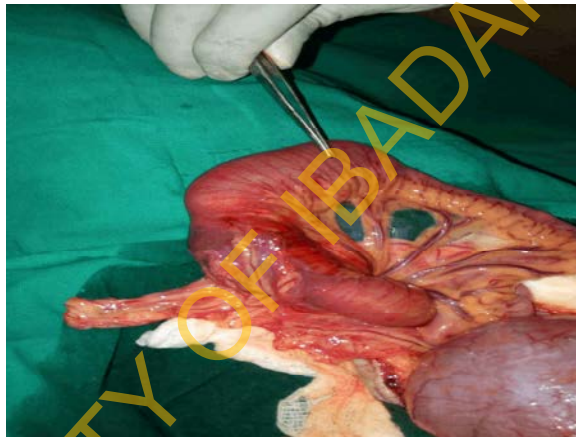
Case 1, Plate 3: Showing towel material being removed from bowel lumen



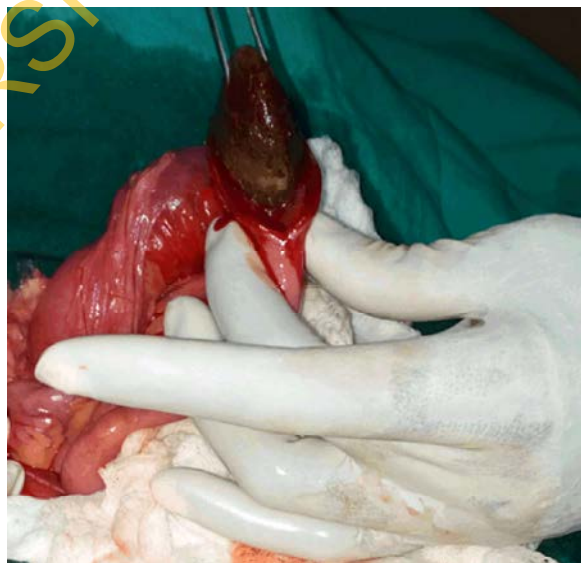Case 2, Plate 4: Left lateral view of radiograph showing gas pocket (Solid blue arrows) and radio opaque foreign materials (Line blue arrows)



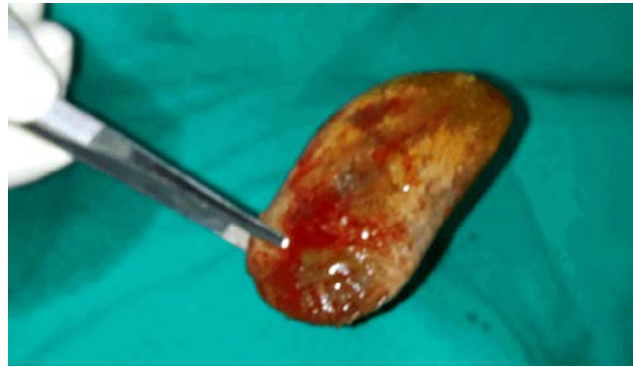
Case 3, Plate 5: Sonogram of patient showing bowel intraluminal foreign body (Blue arrow)



Case 3, Plate 6: Showing showing point of enlargement with intraluminal foreign body



Case 3, Plate 7: Showing foreign body being extracted from bowel lumen



Case 3, Plate 8: Showing foreign body (Mango seed) extracted from bowel lumen

DISCUSSION

The result of the study revealed the level of owners' awareness of pica in dogs in Ibadan, Nigeria. Majority of the dog owners surveyed were adults (Figure 1) with good educational exposure (Figure 2). This may have influenced their access to and utilization of information for prevention of pica habit. This age group also fell into the societal working class that are more security conscious and hence the need for possession of security dogs [17]. Keeping dogs for security and companionship has been an age-long practice that is more common in countries of Europe, Australia, Canada and America than Africa [21]. Although, dog companionship is a secondary reason for dog keeping in Nigeria, it is known to confer enormous benefits [22] such as serving as guide for the visually impaired, protection, enhancing longevity of the elderly by increasing their socialization and physical activity as well as protection [23]. Dog breeding is a stronger reason for dog keeping in Nigeria apart from security concerns and this has been well reflected in the result of this study (Table 1). Many of the exotic breeds have desirable features which make them more costly and hence provide good money for their owners [24, 25]. Nutritional management of exotic breeds is a major challenge in Nigeria. The result of the study shows a major supplementation of commercial food with home ration (Table 1). This situation may also affect the amount of nutrient consumption by such breeds and could compromise their nutritional supply leading to the development of deficiency conditions, including, pica habits. Pica habit has been linked with deficiencies of vital minerals such as zinc and iron, apart from social restraint and boredom; although in some cases the etiology could be idiopathic [3]. Most of the dog owners surveyed are aware of the danger that pica trait pose to their dog's

welfare and have made attempt at preventing the trait and some have even consulted their veterinarians for advice. This information reveals the endemic nature of pica trait in the dog population. In instances where pica was not associated with lack of training, household stimulation or social confinement, a combination of behavioural modification and medication has resulted in a decrease in intensity and frequency of the trait [3]. It is worthy of note that many of the respondent dog owners claim success in preventing their dogs from eating non-food items (Table 1). Pica poses a great danger and severe GIT emergencies in dogs. The cases reported in the study buttress this point. Cases 1 and 2 share similar history. Both dogs of different breeds and from different households ate large pieces of towel that resulted in severe bowel obstruction, plication, multiple perforation sites and peritonitis; early presentation and quick intervention have been identified as key factors for better prognosis in such cases [19]. Imaging modalities were useful in the diagnosis and reaching decision for intervention. Radiology and ultrasonography have been recommended for facilitation of diagnosis of bowel conditions [15, 16]. However, these are not easily obtainable in poor resource settings. Measures taken in the management of these cases were as recommended for intestinal surgery [19]. Nevertheless the prognosis of cases 1 and 2 were guarded due to multiple perforations and ensued peritonitis. Both patients died a day after surgery due to overwhelming septicaemia and toxemia as previously reported [12]. Case three had a better prognosis and survived following surgery.

Dogs should be observed for pica habit and efforts should be made to prevent cultivation of the habit. Veterinarians should make effort to educate owners on pica habit and the danger posed by it to pets' health as well as financial and psychological effects on owners.

PERCENTAGE DISTRIBUTION IN AGE OF RESPONDENTS

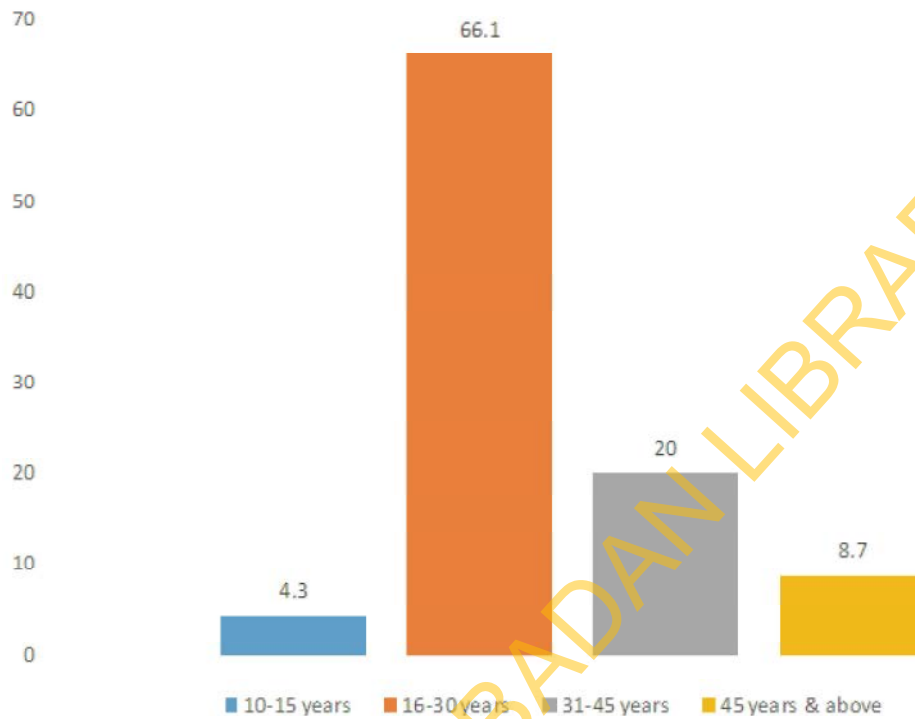


Fig. 1: Showing percentage distribution in age of respondents

MAXIMUM ACADEMIC QUALIFICATION OF RESPONDENTS

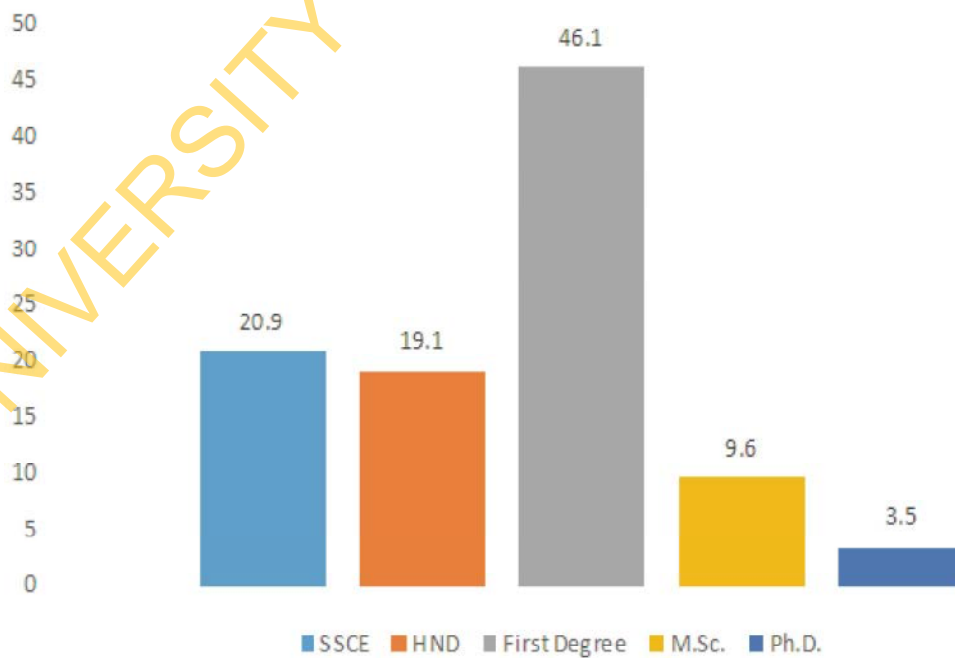


Fig. 2: Showing maximum academic qualifications of respondents

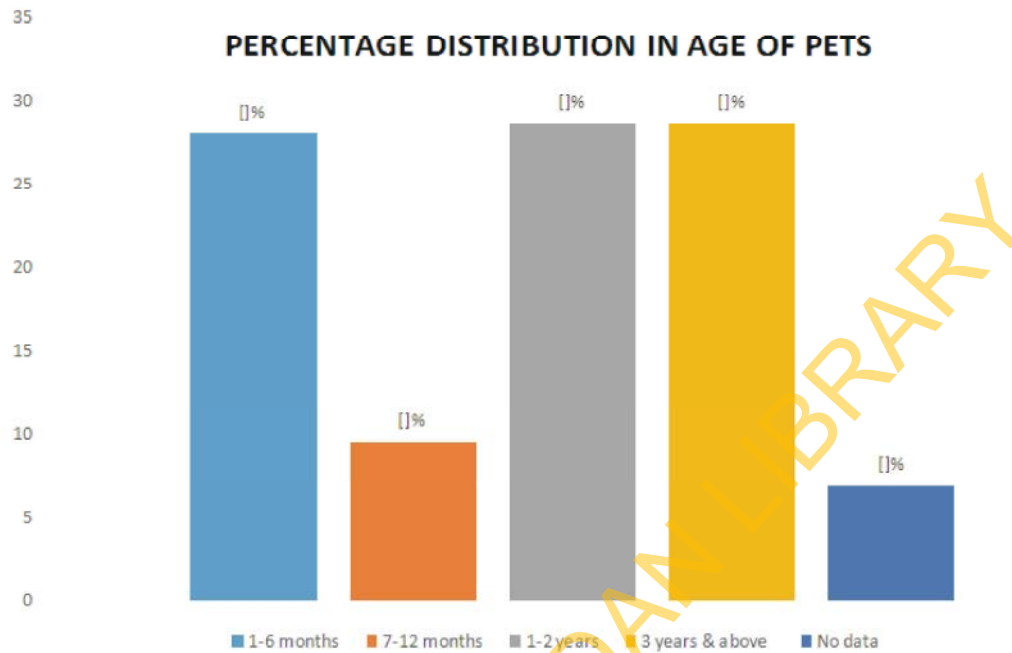


Fig. 3: Showing percentage distribution in age of pets

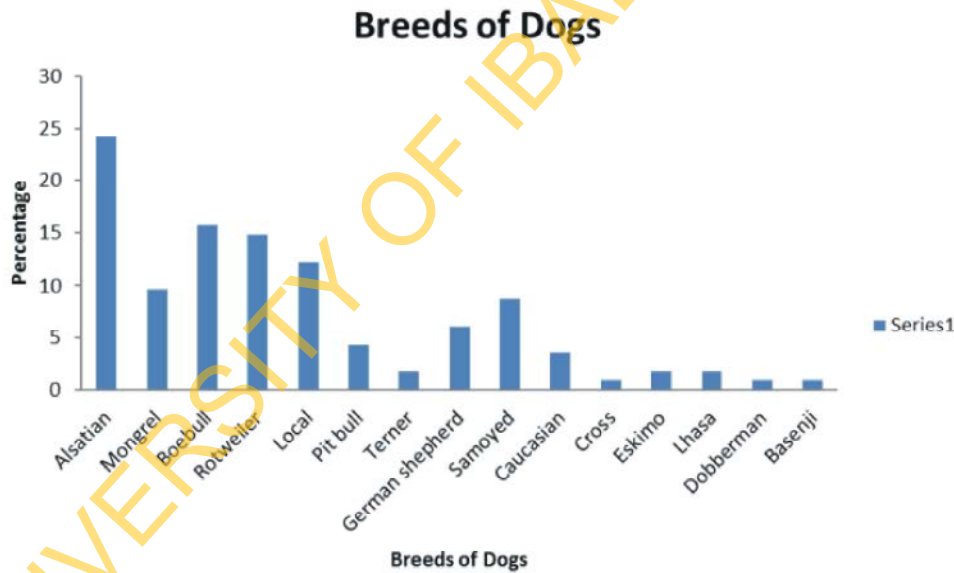


Fig. 4: Showing breeds of dogs owned by respondents

REFERENCES

1. Overall, K.I, 2005. Behavioural Medicine introduction, Normal social behaviour and behavioural problems of domestic animal. In Merck Veterinary Manual 9th Edition and 50th Anniversary edition. C.M. Kahn Ed. Merck and Co. INC. White House Station. NJ. USA. In educational partnership with Merial LMD. A merck and Aventis Company, pp: 132.
2. Rose, E.A., J.H. Porcerelli and A.V. Neale, 2000. Pica: Common but Commonly Missed. The Journal of the American Board of Family Practice, 13(5): 353-358.
3. Overall, K.L. and A.E. Dunham, 2002. Clinical Features and Outcome in Dogs and Cats with Obsessive-Compulsive Disorder: 126 cases (1989-2000). Journal of the American Veterinary Medical Association, 221(10): 1445-1452.

4. Radostits, O.M., G.C. Gay, D.C. Blood and K.W. Hinchillif, 2000. Mastitis In: *Veterinary Medicine*, 9th Edition, Harcourt Limited, London, pp: 603-700.
5. Jahun, B.M., A.Z. Hassan and B.D. Remi-Adewumi, 2007. Intestinal Foreign Body with Concurrent Canine Parvovirus Enteritis in Dog: Case report. *Nigerian Veterinary Journal*, 28(3): 64-65.
6. Penninck, D. and S.L. Mitchell, 2003. Ultrasonography Detection of Ingested and Perforating Wooding Foreign Bodies in Four Dogs. *Journal of the American Veterinary Medical Association*, 223(2): 206-209.
7. Hunt, G.B, C.R. Bellenger and G.S. Allan, 1991. Suspected Cranial Migration of Two Sewing Needles from the Stomach of a Dog. *Veterinary Record*, 1289(14): 329-330.
8. Mshelia, C.P., J.B. Adeyanju, A.A. Abubakar, A.S. Yakubu, A. Jibril, M.Y. Kolo, S. Garba1, M.S. Jibrin and A.G. Balami, 2015. Severe Gastric Impaction in an 8-Year-Old Nigerian Local. *Sokoto Journal of Veterinary Sciences*, 13(1): 57-60.
9. Koike, T., K. Otomo, T. Kudo and T. Sakai, 1981. Clinical Cases of Intestinal Obstruction with Foreign Bodies and Intussusception in Dogs. *Japanese Journal of Veterinary Research*, 29: 8-15.
10. Eyarefe, O.D., T.O. Alonge and E.O. Fayemi, 2011. The incidence of intestinal obstructive diseases in Veterinary Clinics and Hospitals in South Western Nigeria. *Nigeria Veterinary Journal*, 32(1): 36-39.
11. Volvuler, P.A., J. Robert and G.L. Meerdink, 2004. Anuric Renal Failure Associated with Zink Toxicosis in a Dog. *Veterinary and Human Toxicology Journal*, 46(5): 276-278.
12. Darko Capak, Antun Brkić, Ivica Harapin, Dražen Matiečić and Berislav Radišić, 2001. Treatment of the foreign body induced occlusive ileus in dogs *Veterinarski Arhiv*, 71(6): 345-359.
13. Moles, A.D., A. McGhite, O.R. Schaaf and R. Read, 2010. Sand Impaction of the Small Intestine in Eight Dogs. *The Journal of Small Animal Practice*, 51(1): 29-33.
14. Muhammad, S.T., S.W. Audu, B.M. Jahun, M. Lawal and D. Adawa, 2014. Diagnosis and Management of Sand Impaction of the Large Intestine in an Alsatian. *Sokoto Journal of Veterinary Medicine*, 12(2): 57-60.
15. Kuo-Hsien Chiang and Andy Shau-Bin Chou, 2005. Imaging of a Gastrointestinal Foreign Body in a Feline - A Case Report; *Tzu Chi Medical Journal*, 17(3): 187.
16. Vishnu Sunil Jaikumar, Noronha Anjali Antonio, Gadhafi K.P., Varghese Samuel Mathai, Syam K. Venugopal, S. Anoop, C.B. Devanand and Sherin B. Sarangom, 2013. Radiography: a tool for the diagnosis of gastrointestinal affections in chronic vomiting dogs *Indian Journal of Canine Practice*, 5(1): 181-183.
17. Eyarefe, O.D. and S.N. Oyetayo, 2016. Prevalence and Pattern of Small Animal Orthopaedic Conditions at the Veterinary Teaching Hospital, University of Ibadan. *Sokoto Journal of Veterinary Medicine*, 14(2): In Press.
18. Federal Republic of Nigeria Official Gazette, 2007. Summing the 5 Local Government Areas Ibadan North/North West/South West/South East/North East as "Legal Notice on Publication of the Details of the Breakdown of the National and State Provisional Totals 2006 Census". Retrieved, 19 May 2007.
19. Fossum, T.W., S.H. Cheryl, A.L. Johnson, K.S. Schulz, H.B. Seim, M.D. Willard, A. Bahr and G.L. Carroll, 2007. Surgery of the digestive system. In: Fossum, T.W. (Ed.), *Textbook of Small Animal Surgery*. 3rd Edn. St Louis Missouri Elsevier Science, Morsby Inc., pp: 274-449.
20. Lerche, P., A.M. Nolan and J. Reid, 2000. Comparative Study of Propofol or Propofol and Ketamine for the Induction of Anaesthesia in Dogs. *Veterinary Records*, 146(20): 571-574.
21. Kidd, A.H. and R.M. Kidd, 1980: Personality Characteristics and Preferences in Pet Ownership: *Psychology Report*, 46: 939-949.
22. Gumby, P., 1978. Pet for Cardiac Therapeutics. *Journal of American Medical Association*, 241: 438.
23. Hare, B. and M. Tomasello, 2005. The emotional reactivity hypothesis and cognitive evolution. *Trends in Cognitive Sciences*, 10: 464-465.
24. Aline, H. and M. Robert, 1980. Personality characteristics and preferences in pet ownership. *Psychological Reports*, 46: 939-949.
25. Kubinyi, E., B. Turcsán and Á. Miklósi, 2009. Dog and owner demographic characteristics and dog personality trait associations, *Behavioural Processes*, 81(3): 392-401.