



Life saving tail amputation in an African lioness (*Panthera leo* L) in captivity

OD Eyarefe¹, CO Oguntoye^{1*}, TA Olusa² & OA Morenikeji³

1. Department of Veterinary Surgery and Reproduction, University of Ibadan, Ibadan, Nigeria.
2. Faculty of Veterinary and Agricultural Sciences, University of Melbourne, Australia.
3. Department of Zoology, University of Ibadan, Nigeria

*Correspondence: Tel.: +2348055063671, E-mail: wumcel06@yahoo.com

Abstract

This paper reports surgical management of self- tail mutilation in an African lioness triggered by an irritation of unknown aetiology. The lioness was reported to have eaten up to two-third of its tail. Lack of darting facilities delayed quick intervention until the animal was lured with food bait into a restraint cage that enabled chemical restraint and surgical intervention. Tail amputation was performed as described for domesticated canine species. Healing was uneventful with animal returning to normal activities. Tail amputation is an uncommon procedure in wild species. Its curative indication was warranted in this case. There is need for storage of darting facilities in every zoological garden to aid quick intervention and preservation of animals especially endangered species in captivity.

Keywords: Amputation, Lion, Self-mutilation, Tail, Therapeutic

Received: 12-03- 2015

Accepted: 25-08-2015

Introduction

Tail amputation is an uncommon procedure in wild life species. In domesticated animals, especially dog breeds, its performance in conformity with breed's standards or tradition currently generates moral/ethical controversies, although, its therapeutic indications are universally accepted (Hedlund, 2002; Davidson, 2006; King, 2007; Well *et al.*, 2011). Therapeutic tail amputation is indicated in cases of severe tail injury or chronic wounds where conservative management methods have poor prognosis for healing or acceptable cosmetic results (Hedlund, 2002; Aronson, 2003). Septic tail wounds with localized osteomyelitis, if not properly managed, could progress to septicemia and systemic diseases like glomerulonephritis and myocarditis with life threatening consequences (Calvert & Wall, 2006). The associated pains and other neuro-psychological impacts could cause anorexia, unthriftiness, irritation and aggression towards cage mates with several spirally negative effects for captive animals in the zoological garden.

Case presentation

The surgeons at the Department of Veterinary Surgery and Reproduction, University of Ibadan were alerted about the condition of an adult (6 year old) African lioness (Genus: *Panthera leo* L) nicknamed "Dame" kept in captivity at the University of Ibadan Zoological garden. She had had an injury of unknown aetiology at the tip of her tail which she had severely mutilated with much blood loss. The zoological garden has five lions (3 males and 2 females). There was no history of fight with any other lion prior to the injury because they are kept separately in individual cages. Immediate intervention was not possible due to unavailability of darting equipment. Consequently, the handlers resorted to food bait to lure her into a restraint cage where drugs were administered with minimal additional manual restraint techniques six weeks after the wound was first observed. As at the time of surgery, she was emaciated, hyporexic and depressed. She had lost about two- third of her tail, and was left with about fifteen centimeters of residual tail stump, which was messy with blood stain. The wound was necrotic and exudative (Plate I). A decision to stem

the spread of apparent infection by amputation was taken.

Management and outcome

Anaesthesia

The lioness with an estimated body weight of 130kg based on the weight range of 120-250kg in literature for adult African lion (Lamberski,2015), was anaesthetized with 5% Ketamine hydrochloride (Non-proprietary; ROTEXMEDIA LAB, Trittau Germany,) (10mg/kg) and 2% Xylazine hydrochloride (XYL-M2®, VMD, Belgium (1mg/kg). Both drugs were mixed in a syringe and administered as a single bolus at the thigh muscles (Logan *et al.*, 1986, Grassman *et al.*, 2004, Wack, 2005). Onset of action was uneventful.

Surgical procedure

The tail was prepared for aseptic surgery, following which a tourniquet was applied to the base of the tail (tail root) to reduce haemorrhage. Ten millilitres (10ml) of lignocaine hydrochloride (Labcalin®, LABORATE, India) was infiltrated caudal to the tourniquet at the point of proposed amputation, and semi-lunar skin flaps were made, and extended beyond the point of disarticulation.

The skin flaps were retracted cranially. The two lateral and medial caudal vessels were ligated with size 1 catgut (Ethicon, USA), and severed just proximal to the proposed site of transection dorsally and ventrally to expose the coccygeal muscles. The coccygeal muscles were transected and the coccygeal vertebrae disarticulated. The dorsal and ventral skin flaps were pulled over the tail stump and sutured with size 2 nylon (Ethicon USA) using cruciate suture pattern (Plate II).

Postoperative Care

The animal was brought out of the restraint cage into a clean compartment earlier prepared for animal comfort and to prevent possibility of injury that may result from recovery episode with the restraint cage. Cephalexin, 10mg/kg every 12 hours (Dowling, 2010), incorporated in food bit was administered for five days post surgery. The tail wound was also covered with honey as earlier described (Eyarefe & Oguntayo, 2012, Eyarefe *et al.*, 2012). The wound healed uneventfully and sutures were removed three weeks later when the lioness could be lured into the restraint cage under chemical restraint with xylazine–ketamine combination.

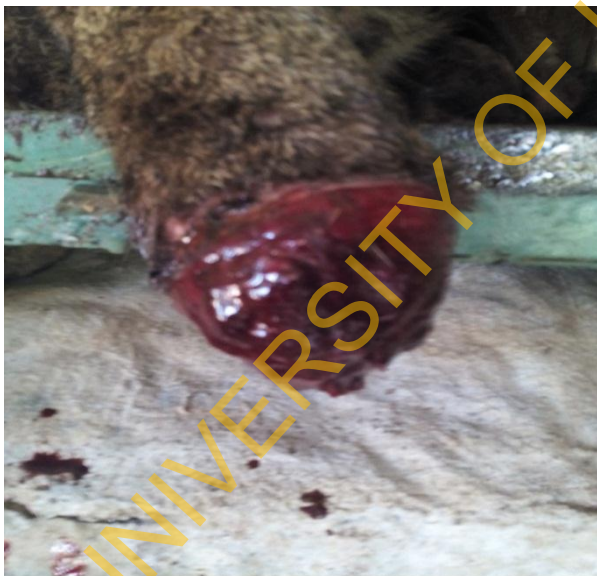

Plate I: Lioness tail showing wound before surgery

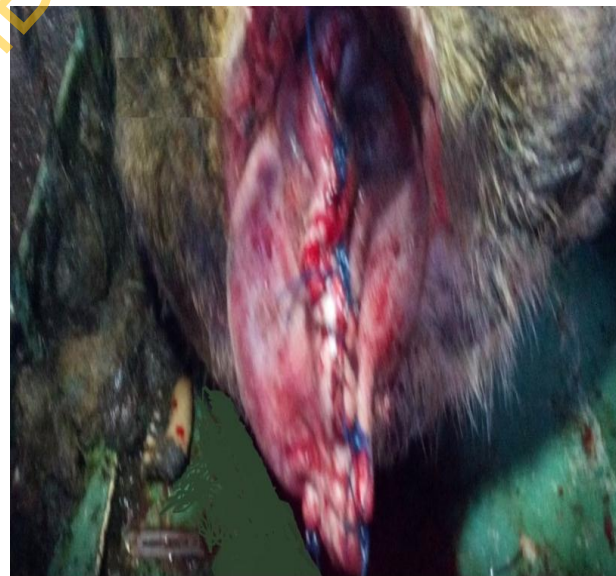


Plate II: Lioness tail showing sutured tail stump

Discussion

Tail amputation in wild life is uncommon. The procedure which is mainly therapeutic has been reported in a single case in association with tail fracture injury sustained through fighting with a cage mate (Olatunji-Akioye *et al.*, 2010). The aetiology of the case under consideration was unknown. The degree and severity of wound and rapidness of self-mutilation was noteworthy. The African lion (*Panthera Leo L*) usually has a tail length of 60-100cm (Sunquist & Sunquist, 2002). A self-mutilation of two-third of this tail length shows the severity of insult and associated self mutilation. A chronic infection process (osteomyelitis) like this may produce septicemia and systemic diseases such as glomerulonephritis, myocarditis and other life threatening diseases (Calvert & Wall, 2006). This was the rationale for the amputation and prophylactic antibiotics therapy. The use of honey dressing in this case was encouraged by previous reports of honey efficacy in prevention of infection and promotion of wound healing in wild species (Eyarefe *et al.*, 2012; Eyarefe & Oguntoye, 2012). The safety of personnel and risk of frequent sedation for wound dressings were also major concerns in this case. The uneventful healing and restoration of the animal to health and normal lifestyle (Plate III) shows the efficacy and effectiveness of the therapeutic methods.

The African lion (*Panthera leo*) is one of the vulnerable wild feline species (Lamberski, 2015). It is currently in the "red list" of the International Union of Conservation of Nature (IUCN) as threatened species, with current conservation status record of extinction in North Africa, near extinction in West Africa, and population of 20,000 across territories in Southern and Eastern

References

- Aronson L (2003). Vertebral fractures and luxations. In: *Text book of small animal surgery. Vol. 1 (Slatter DH, editor)*. WB Saunders Co., Philadelphia Pp 705.
- Bauer H, Packer C, Funston PF, Henschel P & Nowell, K (2015). *Panthera leo*. The IUCN Red List of Threatened Species. Version 2015.2. www.iucnredlist.org, retrieved 27-08-2015.
- Calvert CA & Wall M (2006). Cardiovascular infections. In: *Infectious Diseases of the Dog and Cat (Greene CE, editor)*. Elsevier Saunders, St Louis Pp 841-865.
- Davidson D (2006). Non-therapeutic docking of dogs' tails. *Veterinary Record*, **158**(2):70.
- Dowling M (2010). Chemotherapeutics. In: *The Merck Veterinary Manual tenth edition, (SM Kahn, editor)*. Merck & Co., Inc., White house station, New Jersey, USA. Pp 2273.
- Eyarefe OD & Oguntoye CO (2012). Managing bite wounds in male Mona monkeys (*Cercopithecus mona*). *Tropical Veterinarian*, **30**(1): 47-54.
- Eyarefe OD, Oguntoye CO & Omobowale TO (2012). Managing a necrotic limb of an African dwarf crocodile (*Osteolaemus Tetraspis*) in Ibadan zoological garden. *Nigerian Veterinary Journal*, **33**(1): 395-398.
- Grassman LI, Austin SC, Tewes ME & Silvy NJ (2004). Comparative immobilization of wild felids in Thailand. *Journal of Wildlife Diseases*, **40**(3): 575-578.
- Hedlund CS (2002). Soft tissue surgery. In: *Small Animal Surgery. (Fossum TW, editor)*



Plate III: Lioness post operation.

Africa (Packer *et al.*, 2013). Their threat in the wild have been associated with indiscriminate killing (to protect human life and livestock) and prey base depletion, habitat loss due to human activities (Bauer *et al.*, 2015), and poaching leading to suggestion of fencing of conservation areas (Packer *et al.*, 2011, Packer *et al.*, 2013).

This successful outcome of surgical intervention has helped in the conservation and preservation of an endangered lion species of Africa.

Acknowledgement

The authors acknowledge the University of Ibadan Zoological garden team of animal handlers and the Veterinary surgery Unit animal technologists' team for their assistance during and after the procedure to ensuring the success of the procedure and preservation of a precious species.

- Mosby Inc., St Louis, Missouri. Pp 198-202.
- King R (2007). Docking of dogs' tails. *Veterinary Record*, **160**(3): 99.
- Lamberski N (2015). Felidae. In: *Zoo and Wild Animal Medicine. Eighth edition (Fowler ME & Miller RE, editors)*. WB Saunders Co., Philadelphia. Pp 468.
- Logan KA, Thorne ET, Irwin LL & Skinner, R (1986). Immobilizing wild mountain Lions (*Felis concolor*) with ketamine hydrochloride and xylazine hydrochloride. *Journal of Wildlife Diseases*, **22**(1): 97- 103.
- Olatunji-Akiyoye AO, Omobowale OT, Olaifa AK & Abiola JO (2010). Tail docking in an african lion (*panthera leo*). *Israel Journal of Veterinary Medicine*, **65** (2): 75-76.
- Packer C, Brink H, Kissui BM, Maliti H, Kushnir H & Caro T. (2011). The effects of trophy hunting on lion and leopard populations in Tanzania. *Conservation Biology*, **25**(1): 142–153.
- Packer C, Loveridge A, Canney S, Caro T, Garnett ST, Pfeifer, M , Zander KK, Swanson A, Macnulty D, Balme G, Bauer H, Begg CM, Begg KS, Bhalla S, Bissett C, Bodasing T, Brink H, Burger A, Burton AC, Clegg B, Dell S, Delsink A, Dickerson T, Dloniak SM, Druce D, Frank L, Funston P, Gichohi N, Groom R, Hanekom C, Heath B, Hunter L, Deiongh HH, Joubert CJ, Kasiki SM, Kissui B, Knocker W, Leathem B, Lindsey PA, Maclennan SD, McNutt JW, Miller SM, Naylor S, Nel P, Ng'weno C, Nicholls K, Ogutu JO, Okot-Omoya E, Patterson BD, Plumptre A, Salerno J, Skinner K, Slotow R, Sogbohossou EA, Stratford KJ, Winterbach C, Winterbach H & Polasky S (2013). Large carnivore conservation: dollars and fence. *Ecology Letters*, **16**(5): 635– 641.
- Sunquist, M & Sunquist F (2002). Wild cats of the world. Chicago: University of Chicago Press, Pp 285 - 304
- Wack RF (2003). Felidae. In: *Zoo and Wild Animal Medicine. Fifth edition, (Fowler ME & Miller RE, editors)*. WB Saunders Co., Philadelphia. Pp 491-500.
- Well A, Hill KE, Stafford KJ & Wink WD (2011). The tail injury justification of canine tail docking: Prevalence, causes, treatments and risk factors of canine tail injuries in New-Zealand. Institute of Veterinary Animal and Biochemical Sciences, Massey University, New-Zealand. Pp 1.