

Small Bowel Wall Response to Enterotomy Closure with Polypropylene and Polyglactin 910 Using Simple Interrupted Suture Pattern in Rats

O.D. Eyarefe and S.A. Amid

Department of Veterinary Surgery and Reproduction, University of Ibadan, Nigeria

Abstract: Effects of polypropylene and polyglactin 910 on enterotomy wound healing were investigated. Sixteen adult Wistar albino rats (155.44 ± 30.4 g) were randomized into two study groups, A with polypropylene ($n = 8$) and B with polyglactin 910 ($n = 8$) following 1 cm mid-jejunal enterotomy incisions performed under ketamine/xylazine anaesthesia. Body weights changes were evaluated daily for eleven days and two rats from each group were euthanized at postoperative days 3, 5, 7 and 11. Following euthanasia, the enterotomy sites were examined for dehiscence and adhesion. Evidence of inflammatory reactions and fibroblast proliferation were also evaluated and scored. Leaks from enterotomy site were not observed. Adhesion scores in-group A (3.5) was statistically significant ($p < 0.05$) when compared with group B (1.875). A non-statistically significant ($p > 0.05$) but higher fibroblasts count was recorded in Group A (2.625) compared with group B (1.375). Inflammatory responses in both groups were not statistically significant, although that of Group B was higher in response than group A. Enterotomy closure with polypropylene produced significant adhesion that may be linked with the texture of the suture, and the several knots characteristic of the simple interrupted suture pattern.

Key words: Closure, enterotomy, interrupted pattern, polyglactin 910, polypropylene

INTRODUCTION

There is a growing concern over the most suitable material for the closure of surgical wounds that will enhance rapid healing with minimal postoperative complications. This concern is of prime importance in enterotomy closure with its fatal consequences of adhesion, stricture, leaks, peritonitis, shock and death (Allen *et al.*, 1992; Ralphs *et al.*, 2003). Enterotomies are close conventionally in a single layer of natural or synthetic absorbable sutures, with interrupted or continuous suture patterns (Baines, 2000a). However, closure with non-absorbable sutures has been recommended (Baines, 2000a).

The need for an ideal suture material, especially for the closures of enterotomies, remains the focus of research, because some of the absorbable suture materials weaken over time as they are destroyed by hydrolytic and lysosomal enzymic activities before the wound gains adequate strength; resulting in leaks, peritonitis, and death (Allen *et al.*, 1992; Ralphs *et al.*, 2003). In this study, we compared the intestinal tissue responses to Polyglactin 910 (Vicryl® Ethicon), a braided multifilament synthetic absorbable suture material that has been recommended for both renal and gastrointestinal surgeries Baines, (2000a), with Polypropylene (Prolene® Ethicon), a synthetic non-absorbable, less thrombogenic, and relatively inert suture.

Although polypropylene has been suggested for intestinal surgery (Fossum *et al.*, 2002; Baines, 2000a),

there is a dearth of empirical verification in literature on its efficacy for enterotomy closure. This study aimed at examining intestinal tissue responses to the polypropylene and Polyglactin 910 following enterotomy closure with simple interrupted pattern in rats.

MATERIALS AND METHODS

Experimental animals: This study was conducted at the Department of Veterinary Surgery and Reproduction, University of Ibadan, Nigeria, between February and October 2009. The Faculty ethical committee for usage of animal approved Sixteen (16) adult Wistar albino rats with mean body weight of 155.44 ± 30.4 g for use following assessment of study design for experimental purposes. They were obtained from the Faculty of Veterinary Medicine, University of Ibadan, laboratory animal unit, housed in well ventilated cage compartments with ample space for exercise, and provided with commercial feed (Guinea feeds®) and water ad libitum. The rats were healthy based on clinical examination before commencement of the experiment.

Surgical procedure/experimental design: Following aseptic preparation, and anaesthesia with intramuscular injection of 2% (1 mg/100 gm) Xylazine (Kepro, Holland) and 5% (9 mg/100 gm) Ketamine Hydrochloride (Rotex Medica, Germany), the small intestine was approached via a ventral midline laparotomy. The jejunum was

located, exteriorized, and a 1.0 cm enterotomy was made with a size 10 scalpel blade as described by (Baines, 2000b) and closed with five stitches, either with polypropylene (Group A) or with Polyglactin (910) (Group B) using simple interrupted suture pattern. The laparotomy incision was closed as earlier described (Eyarefe, 2008), and the rats were kept in warm recovery cages. All the rats recovered smoothly from anaesthesia and the mortality rate zero percent (100% survival rate).

Weight measurement: Each rat's daily postoperative body weight changes were monitored with a weighing scale (Salton Emperor®).

Evaluation of intraabdominal adhesions: Two rats from each group were euthanized at days 3, 5, 7, 11 with diethyl ether and their enterotomy sites and adjacent visceral surfaces evaluated for evidence of adhesion. Observed adhesions were scored according to Granat adhesion score (Granat *et al.*, 1983).

Histopathological examination: A section of intestinal tissues including the enterotomy sites was harvested from each rat into 10% formalin, processed and stained with haematoxylin and eosin, and evaluated with light microscope. The numbers of inflammatory cells and fibroblasts observed were scored based on their density on each field as earlier described by Sahin *et al.* (2001).

Statistical analysis: The t-test was used to comparison of mean differences in both groups. A <0.005 was considered statistically significant.

RESULTS

Figure 1 shows the differences in average preoperative and postoperative body weights changes in polypropylene group compared with polyglactin 910. Both groups recorded a fall in body weight, with polypropylene group losing an average of 10.3g between 3 to 11 days post- surgery.

Figure 2, Plate 1 and 2 show the inflammatory cell responses to polypropylene and polyglactin 910 using simple interrupted suture pattern. Polyglactin 910 exhibited a lower response at day 3 but a higher response at days 4 and 7. The response to both suture materials fell below the initial levels at day 11. The difference in inflammatory cell response was not significant ($p>0.05$)

Fibroblast responses to wound closure with polypropylene and polyglactin 910 using simple interrupted suture pattern are shown in Fig. 3, Plate 1 and 2. Polypropylene had a consistently higher adhesion score ($p<0.05$) at days 3, 7 and 10 when compared with polyglactin 910.

Figure 4 shows adhesion scores in wound closed with polypropylene and polyglactin 910 using simple interrupted suture patterns.

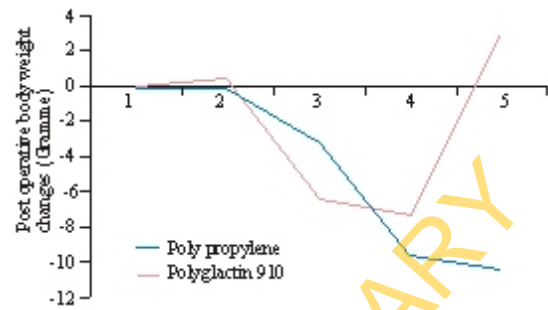


Fig.1: The differences in average preoperative and postoperative body weights changes in polypropylene group compared with polyglactin 910

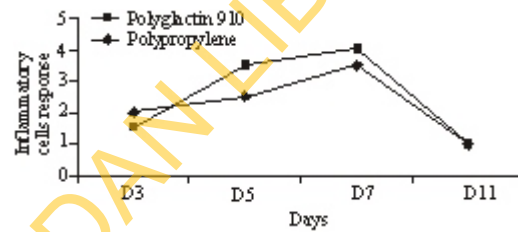


Fig. 2: Inflammatory cell responses to polypropylene and polyglactin 910 using simple interrupted suture pattern

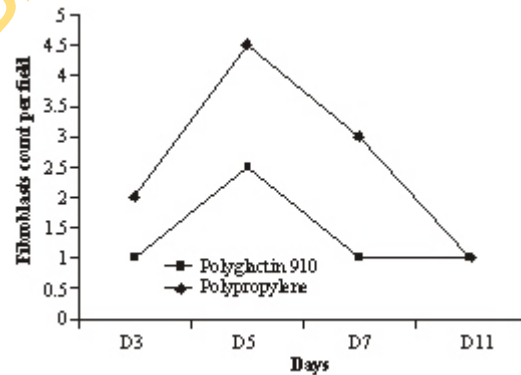


Fig. 3: Fibroblast responses to wound closure with polypropylene and polyglactin 910 using simple interrupted suture pattern

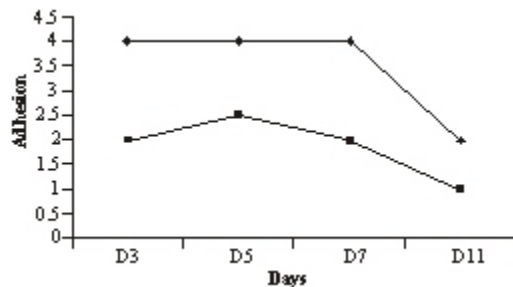
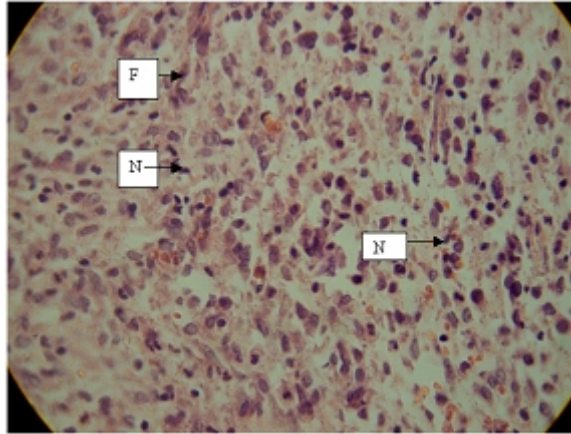
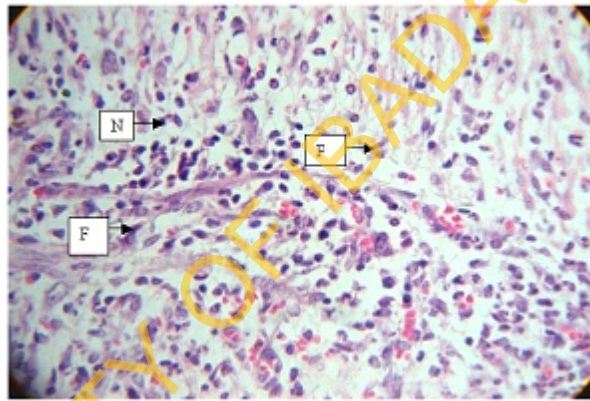


Fig. 4: Adhesion scores for wound closed with polypropylene and polyglactin 910 using simple interrupted suture pattern



N = Neutrophils, F = Fibroblasts

Plate 1: Micrographs sections showing inflammatory cells and fibroblast response to enterotomy closure with polypropylene using simple interrupted pattern at postoperative day 5 (x400)



N = Neutrophils, F = Fibroblasts

Plate 2: Micrographs sections showing inflammatory cells and fibroblast response to enterotomy closure with Polyglactin 910 using simple interrupted pattern at postoperative day 5 (x400)

DISCUSSION

The result of the study shows the effects of polypropylene and polyglactin 910 on enterotomy wound healing using a simple interrupted suture pattern. Wound healing following intestinal injury is of potential importance to the surgeon since wound dehiscence of an intestinal anastomosis often leads to bacterial peritonitis and subsequent death (Ellison, 1989; Allen *et al.*, 1992; Ralphs *et al.*, 2003). The lag or inflammatory phase of healing commences immediately following intestinal injury and last three to four days (Ellison, 1989). The observed prolongation of the inflammatory phase until the fifth day may be due to inflammatory cell response to infection since the rats were not on antibiotics before or after the surgery (Fig. 2). It has been reported that sutures used for apposition of wound edges offer the main support

during the inflammatory phase of wound healing, although the fibrin clot also offers some degree of wound support on the first postoperative day (Ellison, 1989; Baines, 2000a). The inflammatory phase has been reported to be the most critical period of intestinal wound healing, since most dehiscences take place within 72 to 98 h following intestinal wound creation (Ralphs *et al.*, 2003; Ellison, 1989; Baines, 2000a). However, in this study the mortality rate was zero showing that the rats fare well through this period. Moreover, the lower inflammatory cell response in the polypropylene group could be a reflection of the relative inertness of polypropylene, which had earlier been reported (Boothe, 1985; Sahin *et al.*, 2001). The result of fibroplasia as observed in this study is consistent with similar finding by other investigators (Peacock, 1984). Rapid proliferation of fibroblast occurs between the 3rd and 14th day of

intestinal injury resulting in production of large amount of collagen and rapid gain of wound strength (Peacock, 1984; Ellison, 1989; Baines, 2000a). At the end of 14 days, small intestinal wound bursting strength is approximately 75% of normal tissues (Ellison, 1989). In this study, there is an observed relationship between the higher fibroplasia and the adhesion observed in the polypropylene group. Since fibroblasts are the precursors of collagen also involved adhesion, the higher fibroplasia may be due to the severe adhesion observed in this group.

Furthermore, rats in the two groups had initial slight body weight loss between days 0 and 3 that may be due to catabolic weight loss from surgical stress and wound healing (Eyarefe, 2001). However, the consistent and prolonged weight loss in polypropylene group (Fig. 1) could be attributed to reduced intake of food and water precipitated by the postoperative pain induced by the severe adhesion (Frecknell, 1989) observed in polypropylene group.

CONCLUSION

Although polypropylene possesses attributes of an ideal suture, as could be observed in this study, it may be postulated that its use for enterotomy closure with the conventional simple interrupted sutures may not be advisable. The authors are of the opinion that the several knots characteristic of the simple interrupted pattern may be contributory to the observed adhesion in the polypropylene group.

REFERENCES

- Allen, D.A., D.D. Smeak and E.R. Schertel, 1992. Prevalence of Small Intestinal dehiscence and associated clinical factor; a retrospective study of 121 dogs. *J. Am. Anim. Hospital Assoc.*, 28: 70-76.
- Baines, S., 2000a. Surgical techniques for disease of the small intestine in dogs and cats. *Practice*, 20(10): 502-517.
- Baines, S., 2000b. Surgical techniques for disease of the small intestine in dogs and cats 2. *Practice*, 20(10): 574-592.
- Boothe, H.W., 1985. Suture Materials and Adhesives. In: Slatter, D.H. (Ed.), *Textbook of Small Animal Surgery*. Philadelphia, WB Saunders, pp: 334.
- Ellison, G.W., 1989. Wound healing in gastrointestinal tract. *Semin. Vet. Med. Surg.*, 4: 287.
- Eyarefe, O.D., S.O. Oni and J.F. Akinrinmade, 2001. Clinicopathological features of massive small intestinal resection in Nigeria's Local Breeds of Cats. *Afr. J. Biomed. Res.*, 4: 33-37.
- Eyarefe, O.D., B.O. Emikpe and O.A. Arowolo, 2008. Small bowel responses to enteral honey and Glutamine administration following small bowel resection in rabbits. *J. Medic. Med. Sci.*, 37(4): 309-314.
- Fossum, T.W., C.S. Hedlund, D.A. Hulse, A.L. Johnson, H.B. Seim, M.D. Wilford and G.L. Carrol, 2002. *Surgery of the digestive system in small animal surgery*. Mosby, St Louis, pp: 274-449.
- Frecknell, P.A., 1989. Management of Postoperative pain in Laboratory Animal Anesthesia: An Introduction to Research Workers and Technicians. Academic Press Inc., San Diego, CA., pp: 83.
- Granat, M., I. Tur-kespa, E. Zylber-Katz and J.C. Schenker, 1983. Reduction of peritoneal adhesion formation by Calcichine in comparative in a rat. *Fertil. Steril.*, 40: 369-372.
- Peacock, E.E., 1984. *The Gastro Intestinal Tract: Surgery and Biology of Wound Repair*. 3rd Edn., WB Saunders, Philadelphia.
- Ralphs, S.C., C.R. Jessen and A.J. Lipowitz, 2003. Risk factor for leakage following intestinal anastomosis in dogs and cats: 115 cases (1991-2000). *J. Am. Vet. Med. Assoc.*, 223(1): 73.
- Ramsey, C. and F. Knoch, 2010. The Role of Sutures in Wound Healing. Retrieved from: <http://www.infectioncontroltoday.com>. (Accessed date: April 15, 2010).
- Sahin, M., M. Karademir, S.A. Ozer, R.M. Caglayan, F. Aksoy and M. Aktan, 2001. Effects of different suture techniques on wound healing in abdominal wall closure. *Turk. J. Med. Sci.*, 31: 391-394.